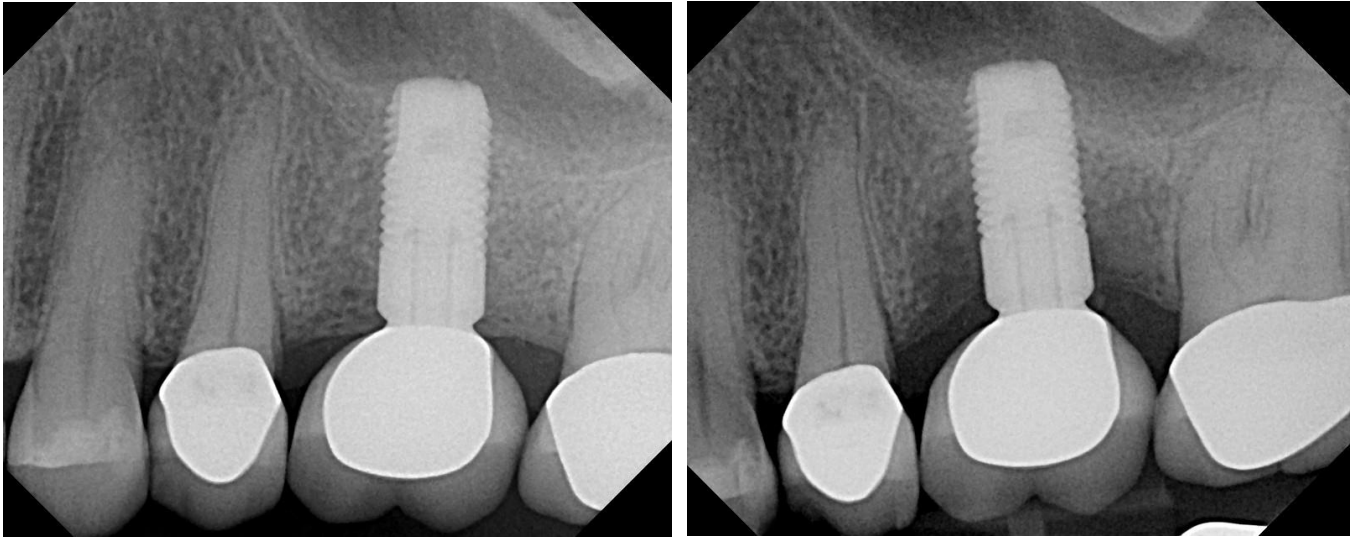

47 Consecutive Steiner Sinus Lift Cases

ID: Fair

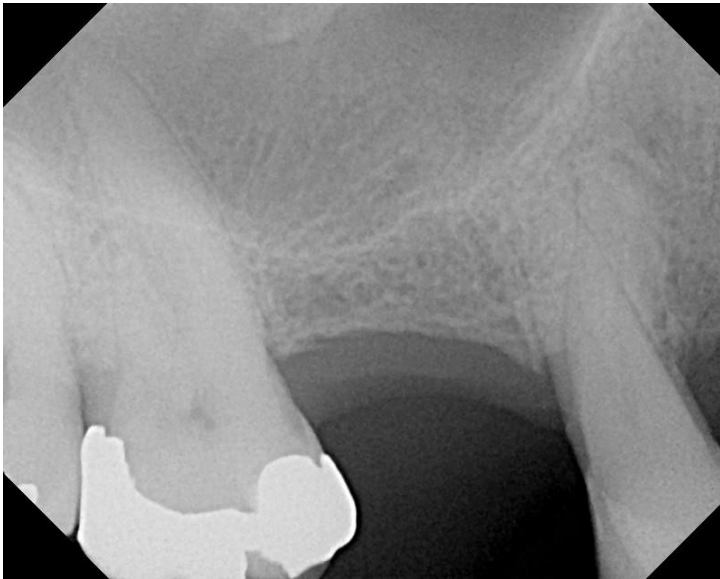
#1



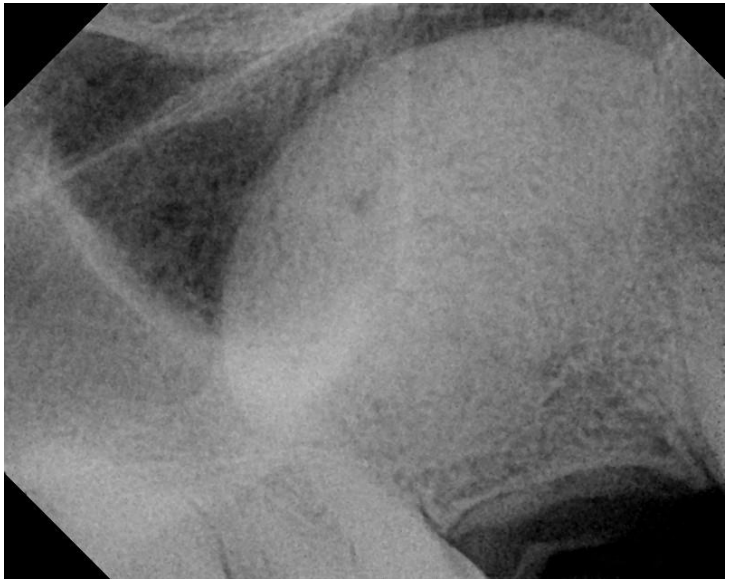On 12/11/2007 tooth #14 was extracted and grafted with an allograft. On 06/11/2008, Steiner Sinus lift was done and an implant was placed at the same appointment. On 02/16/2012, in the second radiograph, the allograft failed and the implant was retained by the sinus augmentation only. The implant remains in function with a poor prognosis. Failure of allografts and xenografts around implants is due to the sclerotic bone produced may these materials. As a result removal of the allograft or xenograft and grafting with Socket Graft Putty is advised prior to implant placement. As of 2015 this implant is still in place retained only by the bone created in the sinus.

ID: Nix

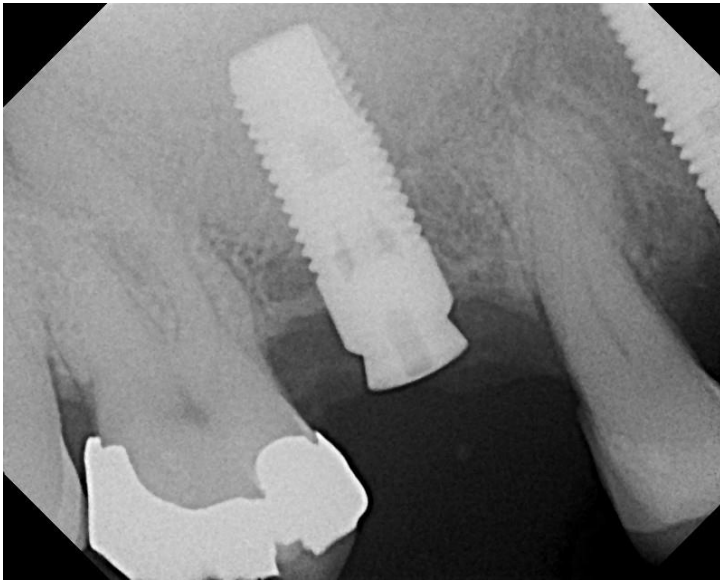
#2



Pre op

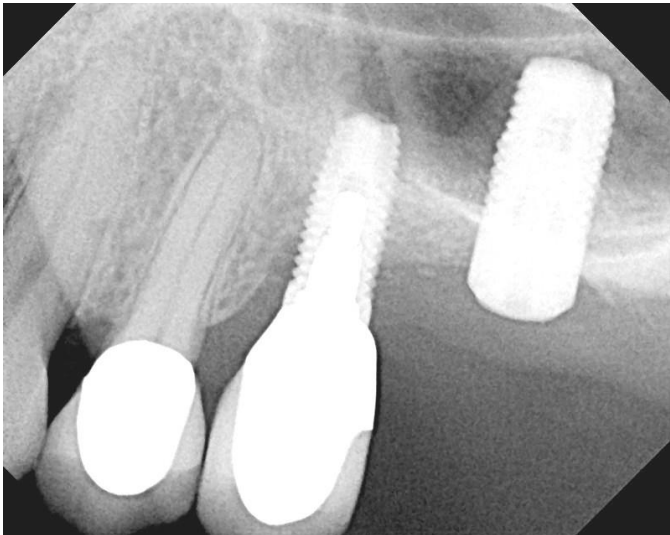


10/27/09 Steiner Sinus Lift complete.

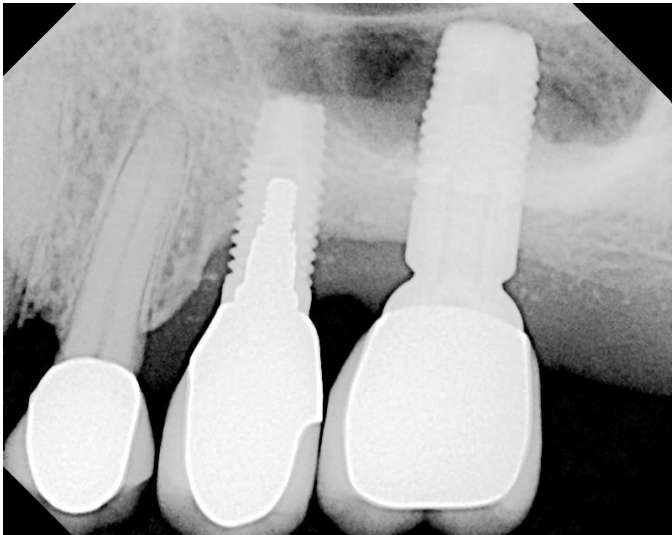


10/27/09 Implant placed.

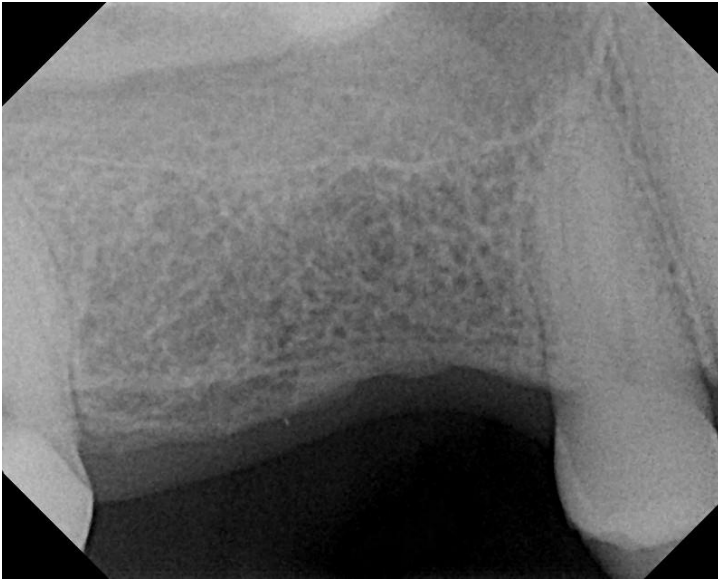
ID: Dici
#3



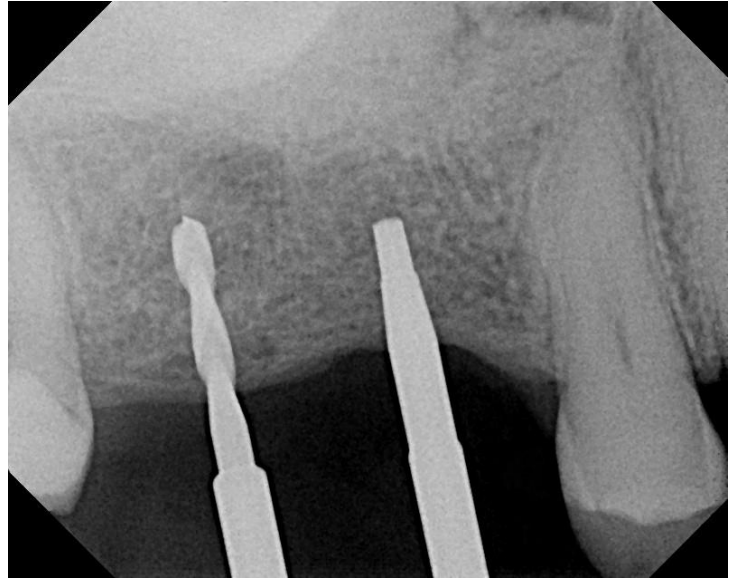
11/10/2009 Healing abutment



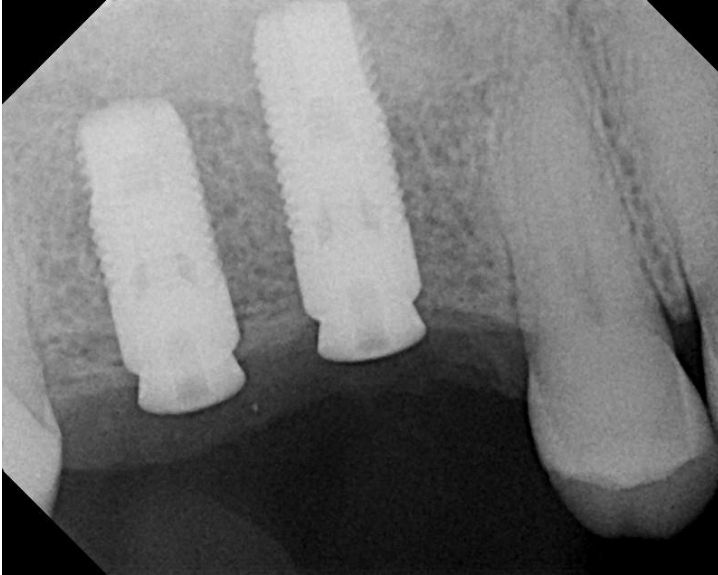03/20/10 Restored



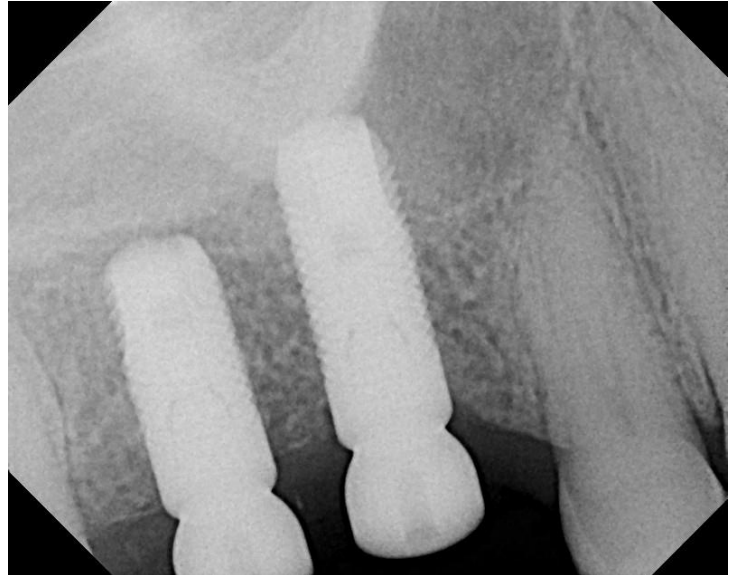Pre op



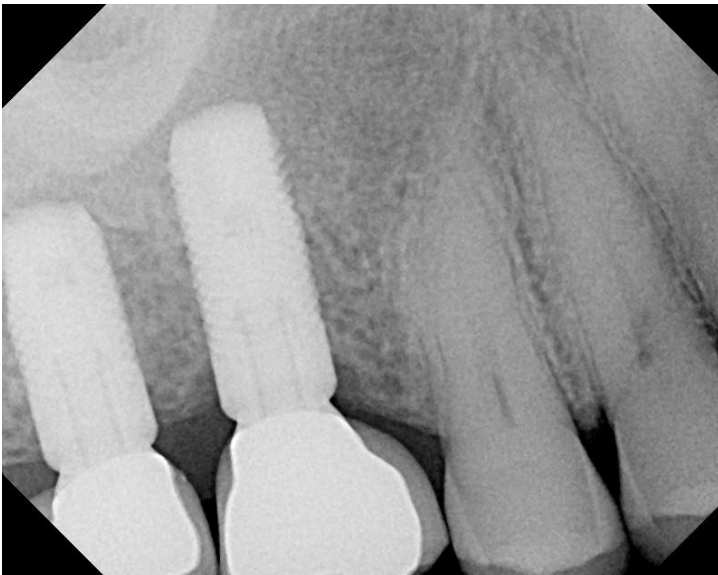11/12/2009 Steiner Sinus Lift complete.



11/12/2009 Steiner Sinus Lift complete.



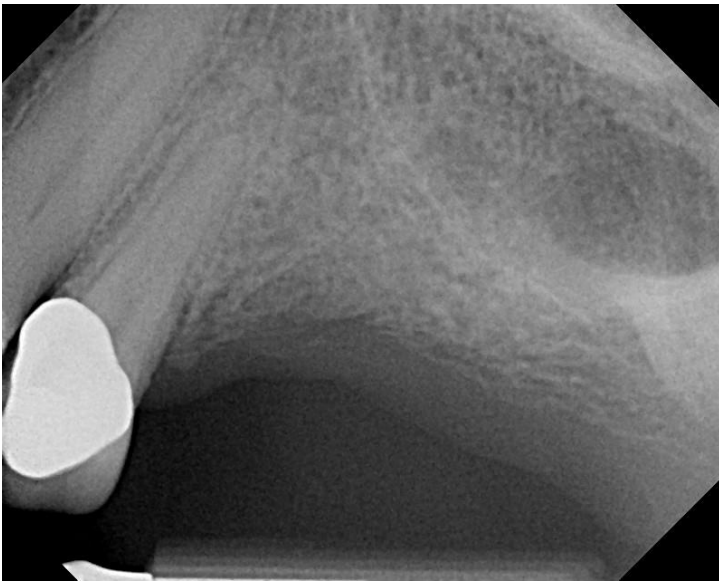
02/12/2010 Healing abutments placed & referred for restoration.



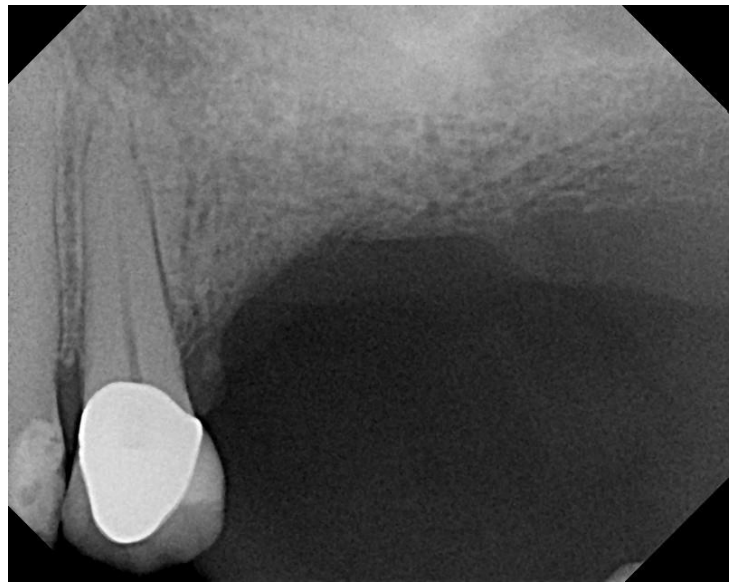
05/26/2010 Implant post op evaluation.

ID: Wea

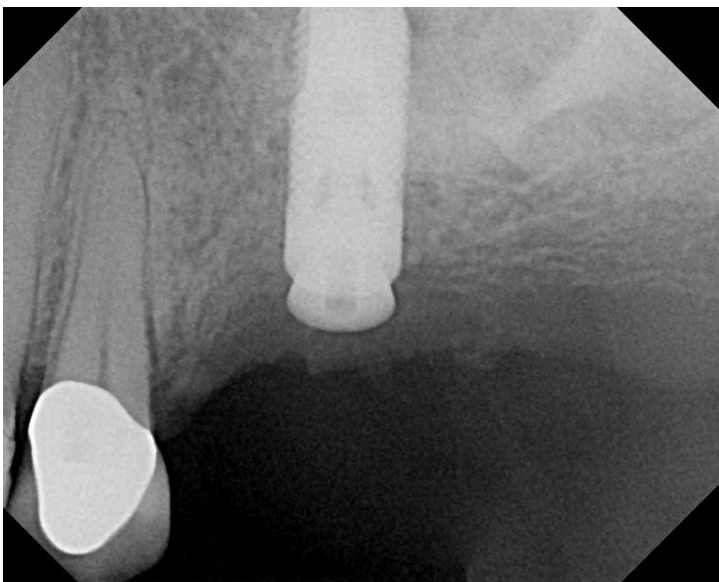
#5



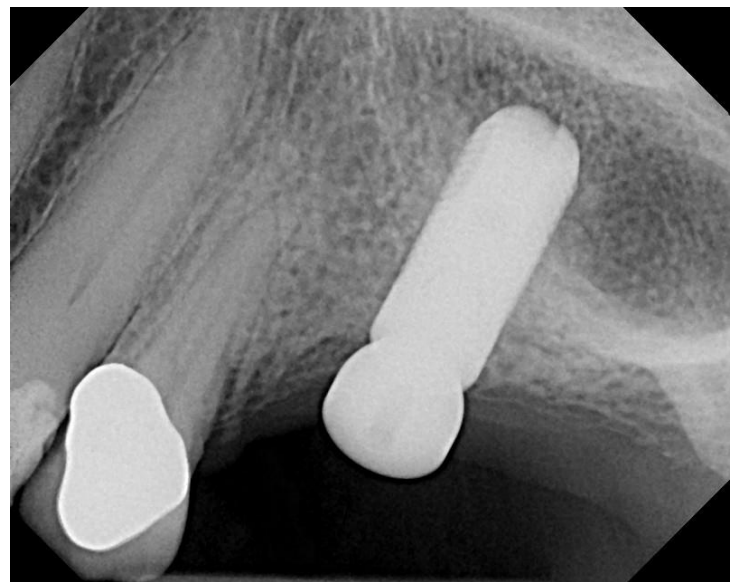
Pre op



12/15/2009 Steiner Sinus Lift complete.



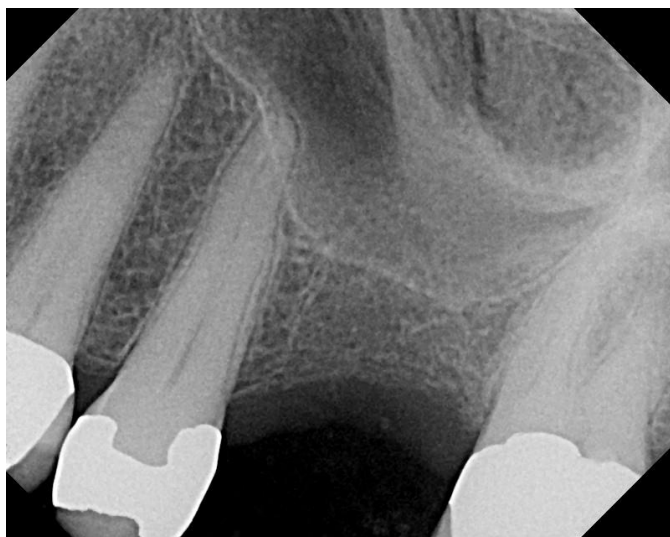12/15/2009 Steiner Sinus Lift complete with implant.



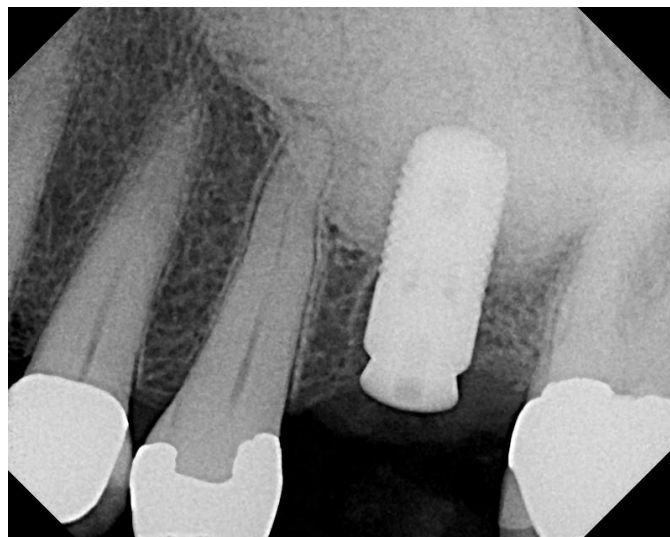03/17/2010 Healing abutment placed & referred for restoration.

ID: Ame

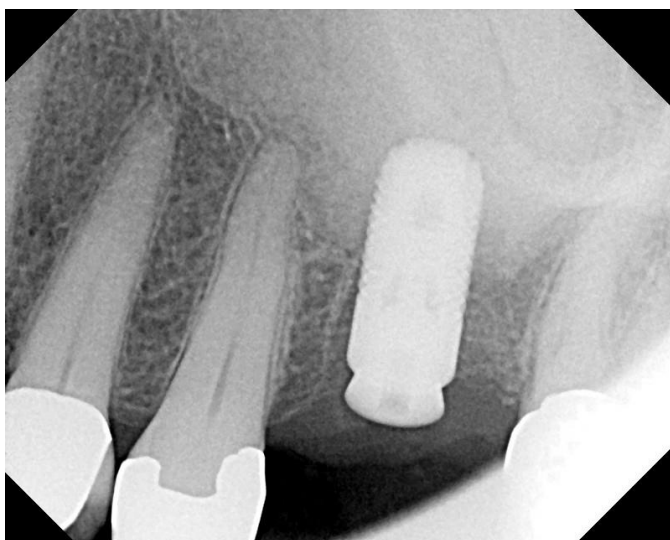#6



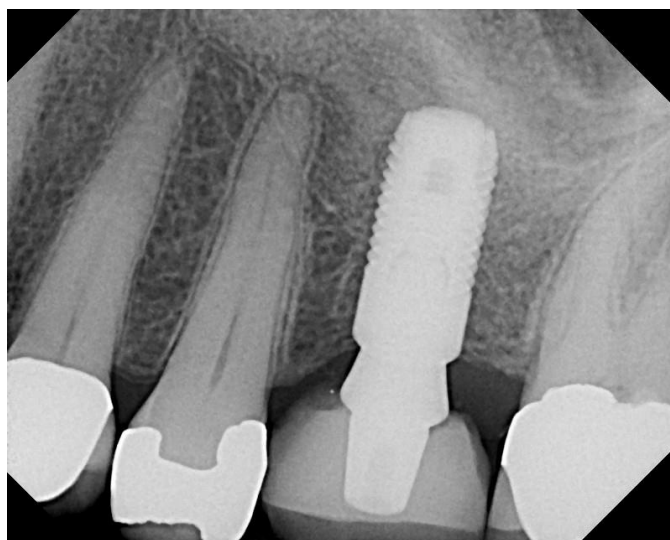
Pre op



Steiner Sinus Lift with Sinus Graft™ implant placement
02/18/10.



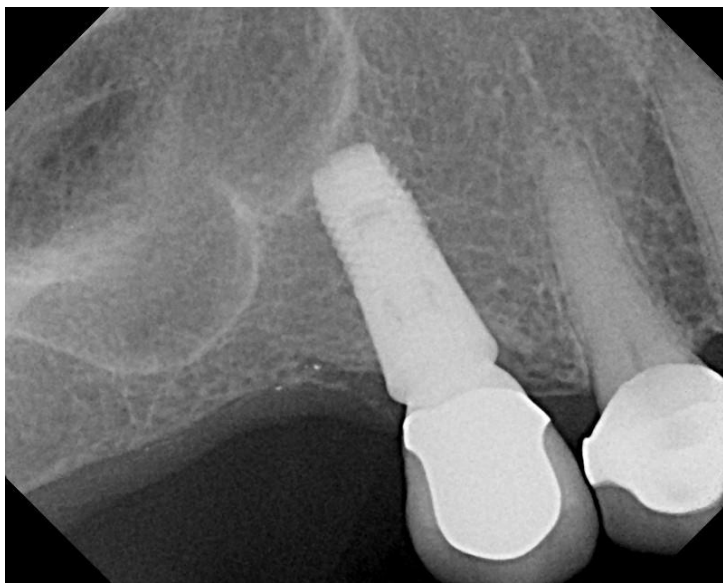Healing abutment 3/2/10



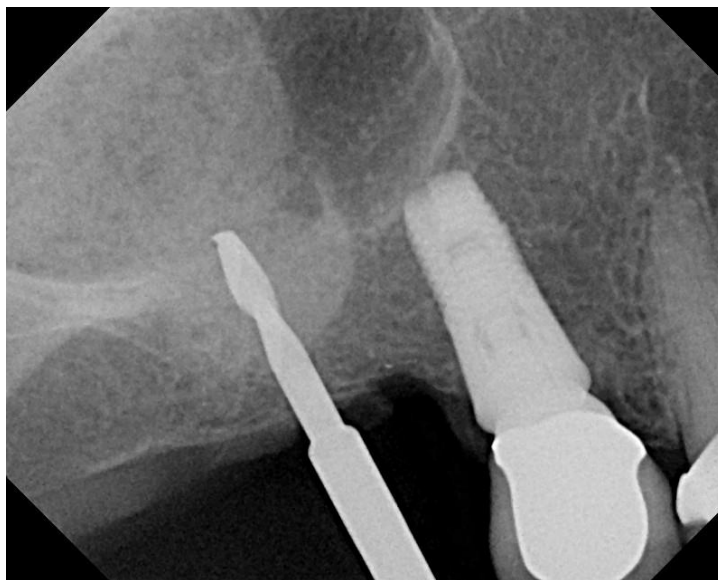
Restored 3/14/10

ID: Nav

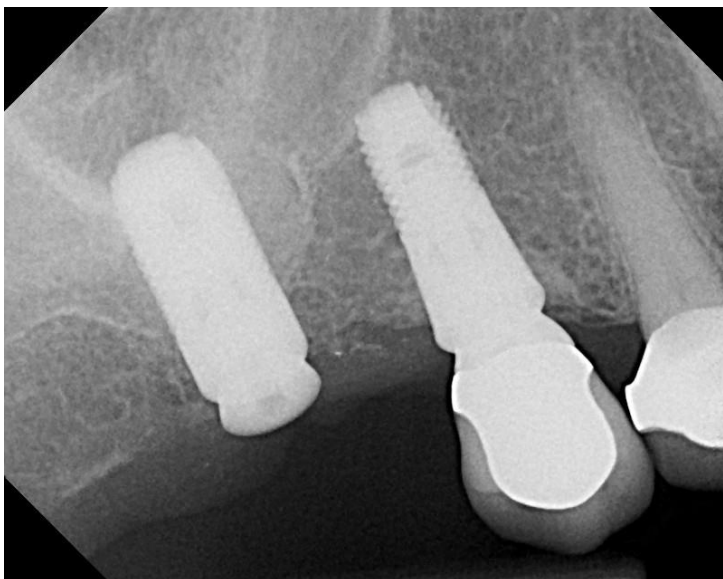#7



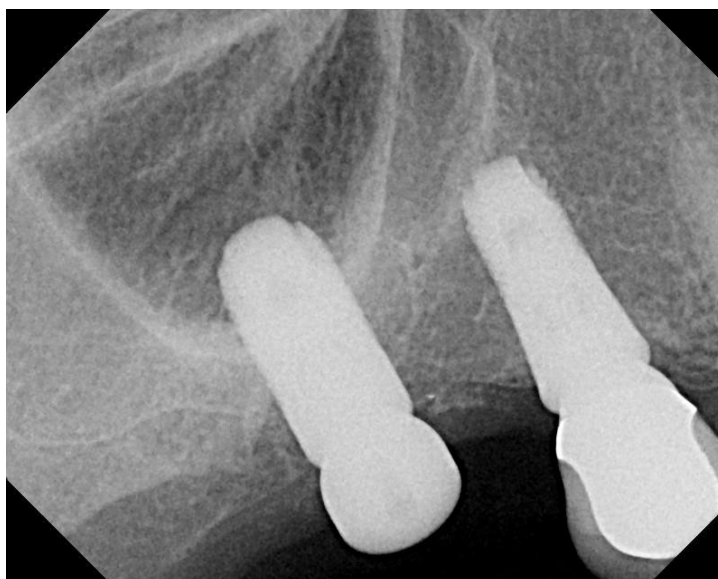
Pre op



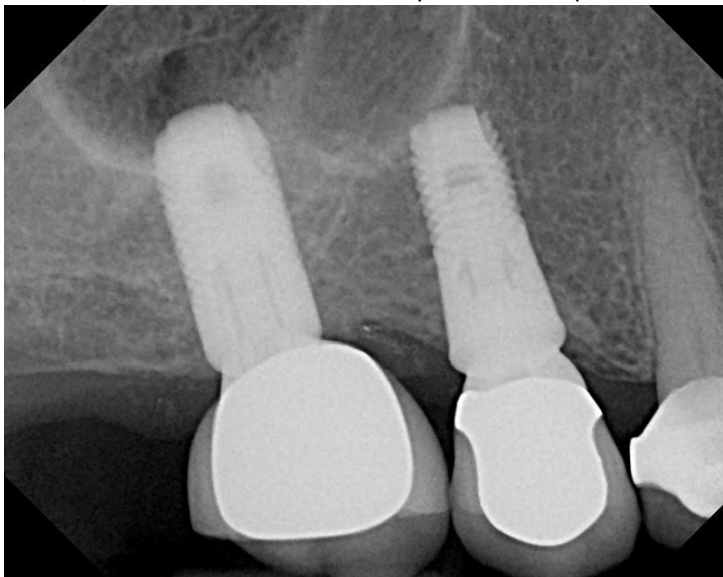
02/18/2010 Steiner Sinus Lift complete



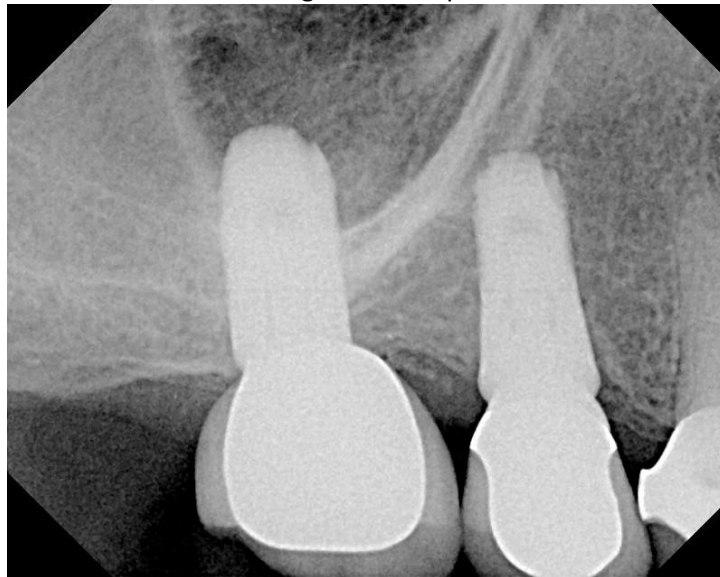
02/18/2010 Steiner Sinus Lift complete with implant



05/13/2010 healing abutment placed



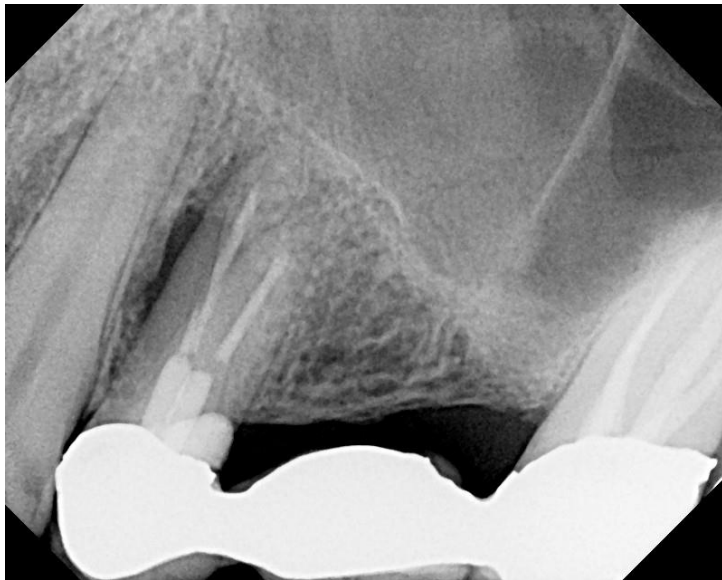04/10/2012 Post op evaluation of restoration



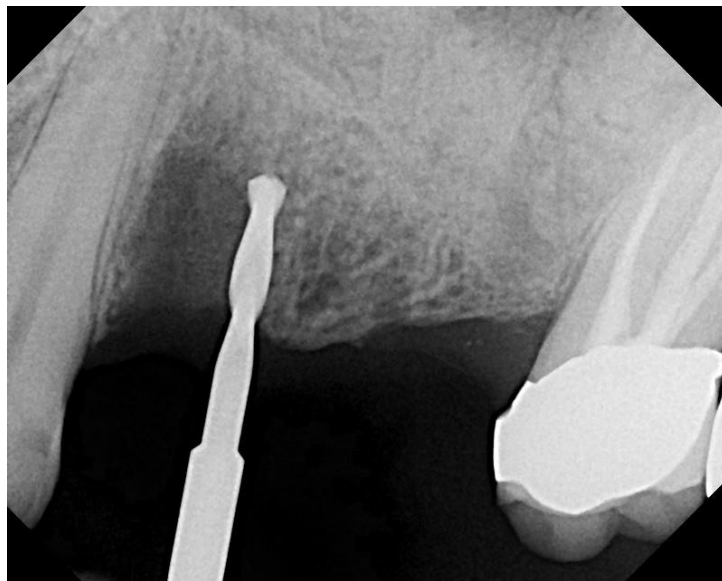
3 years later, X-Ray taken 4/28/15

ID: McK

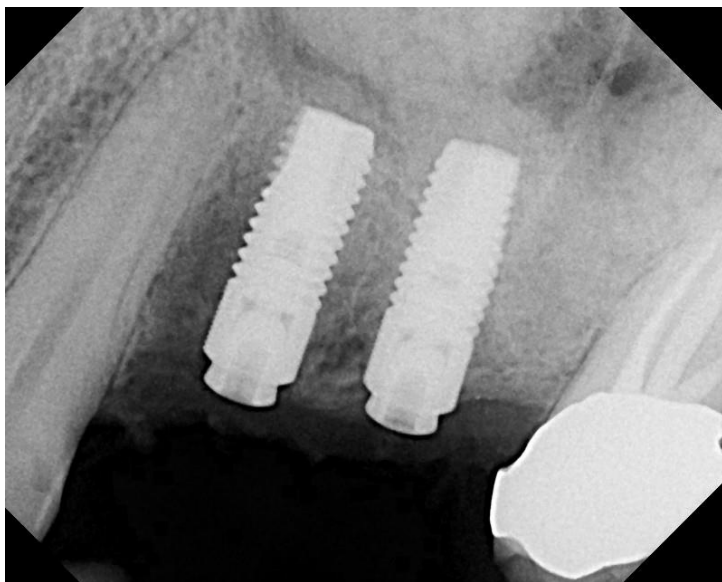
#8



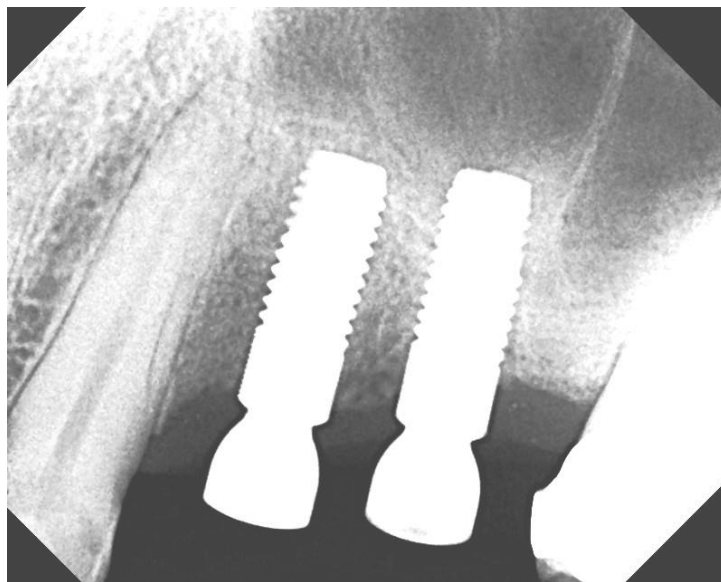
#12 extracted and grafted with Socket Graft.



03/03/2010 Steiner Sinus Lift complete.



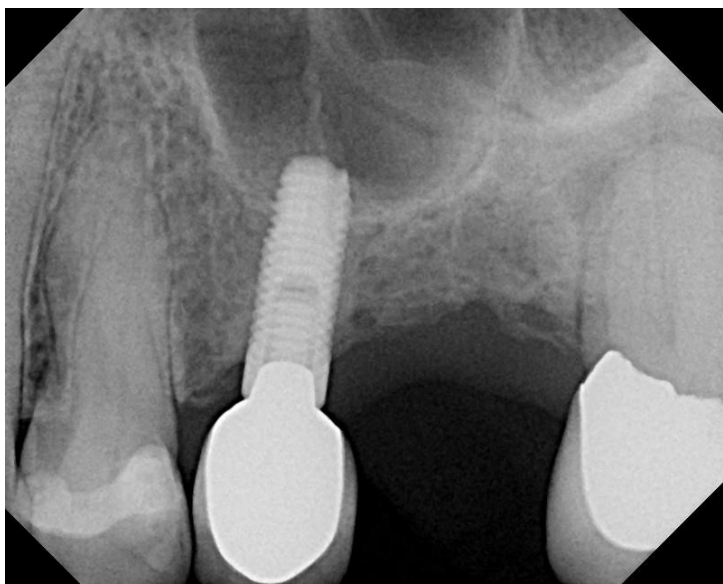
03/03/2010 Steiner Sinus Lift complete with implants.



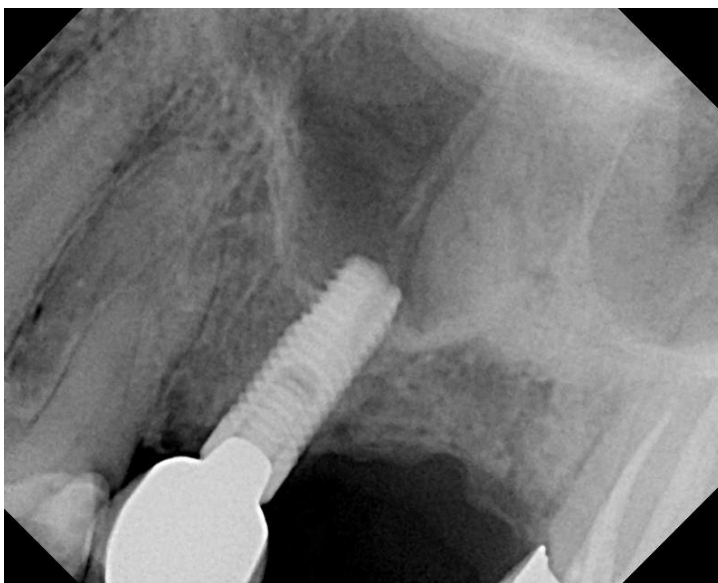
05/25/2010 Healing abutments placed and refer for restoration.

ID: Tur

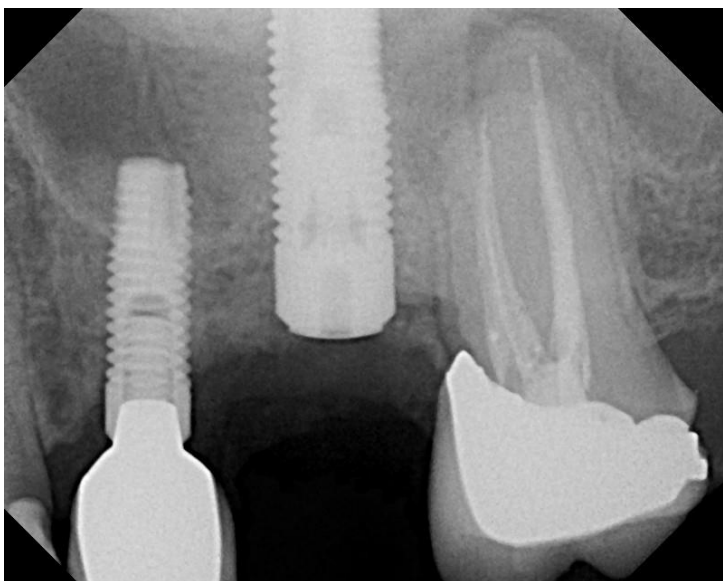
#9



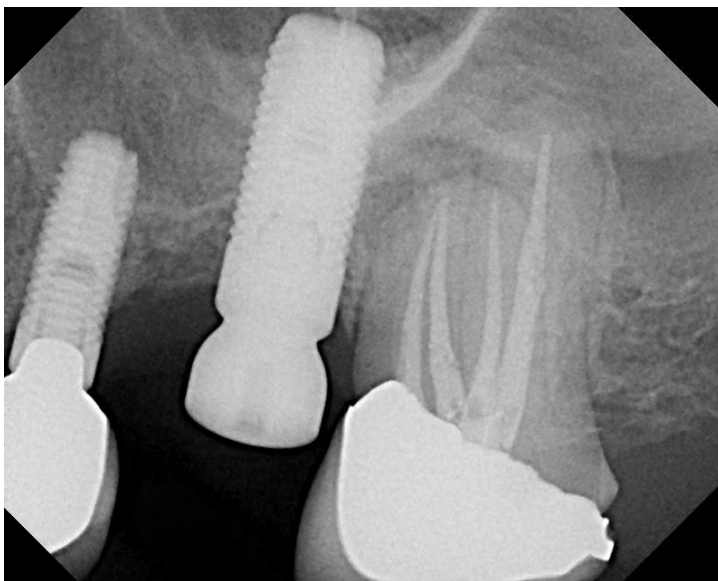
Pre op



03/04/2010 Steiner Sinus Lift complete.



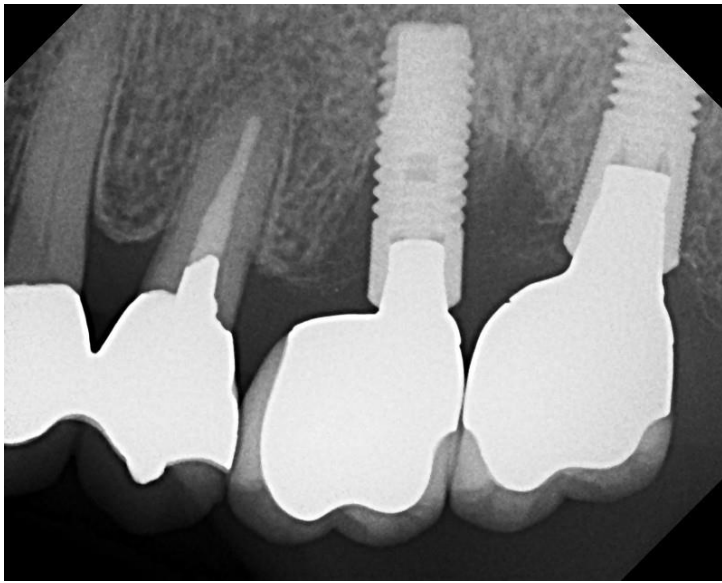
03/04/2010 Steiner Sinus Lift complete with implant.



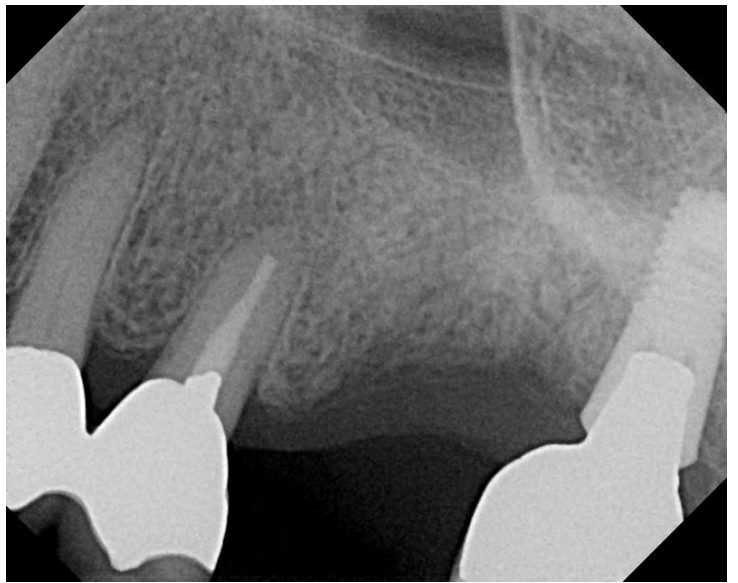05/25/2010 Healing abutment appointment referred for restoration.

ID: Mil

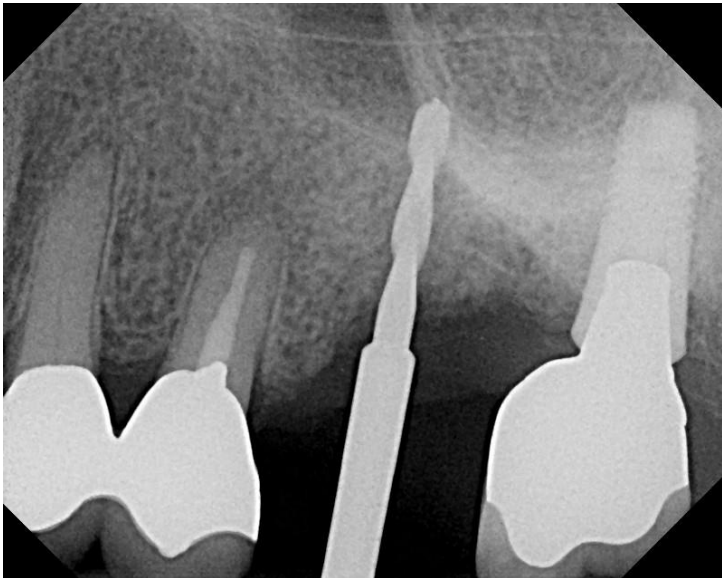
#10



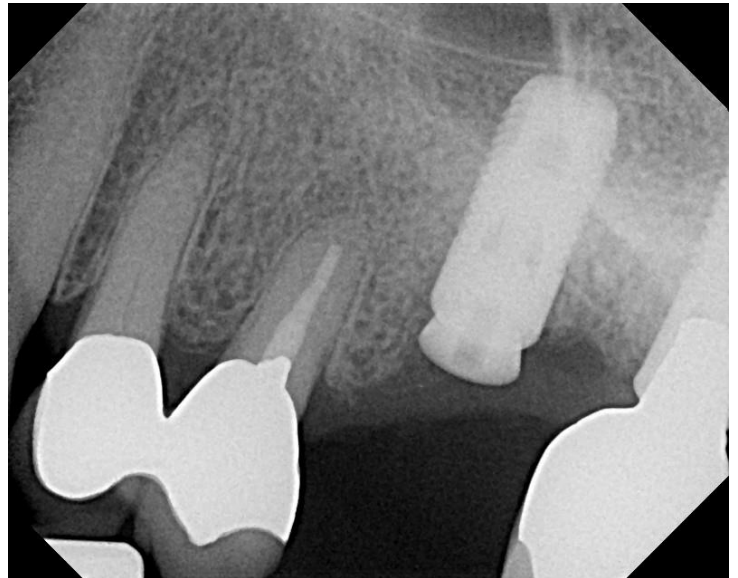10/13/2010 pre op



03/18/2010 failing implant extracted and grafted with Socket Graft.

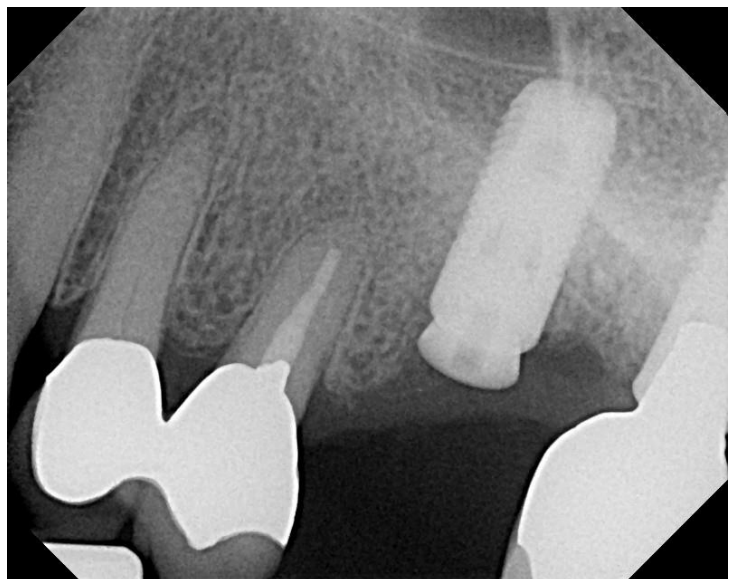

10/13/2010 Steiner Sinus Lift complete.



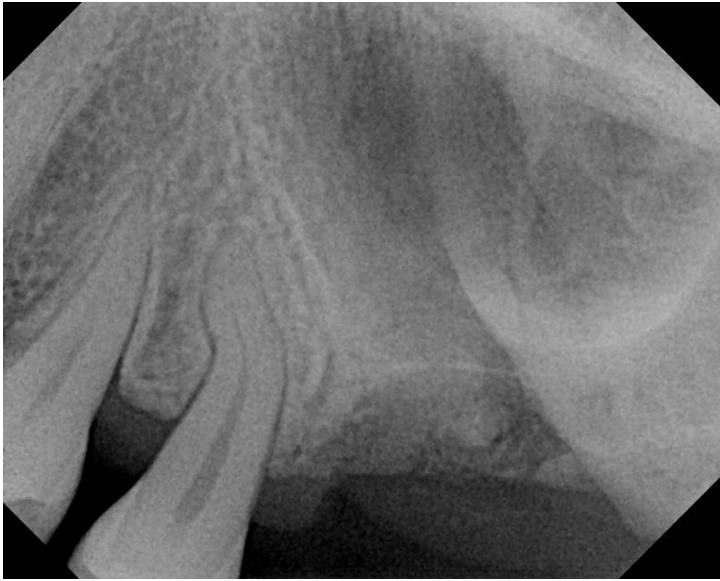10/13/2010 implant placed.

01/18/2011 Healing abutment date referred for restoration.

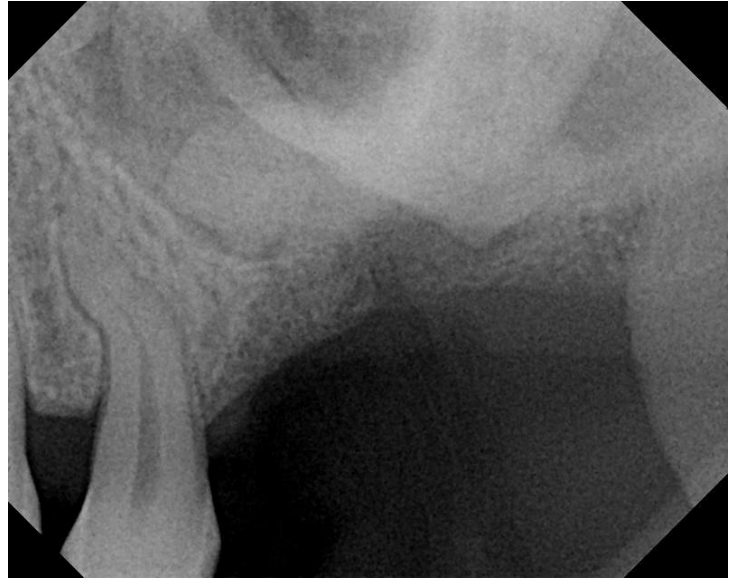

ID: Lad

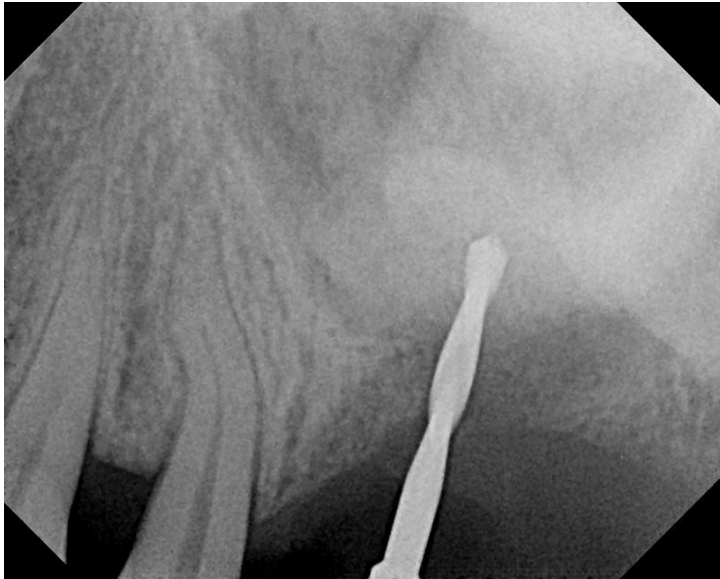#11



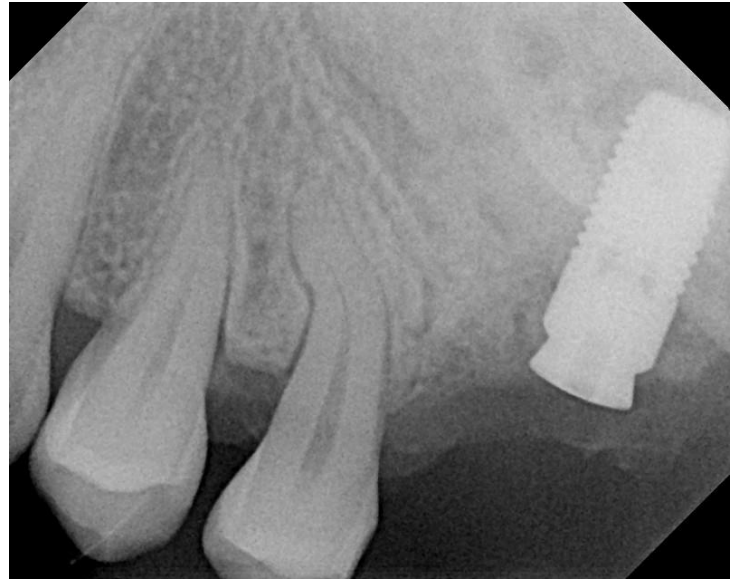04/01/2010 Pre op



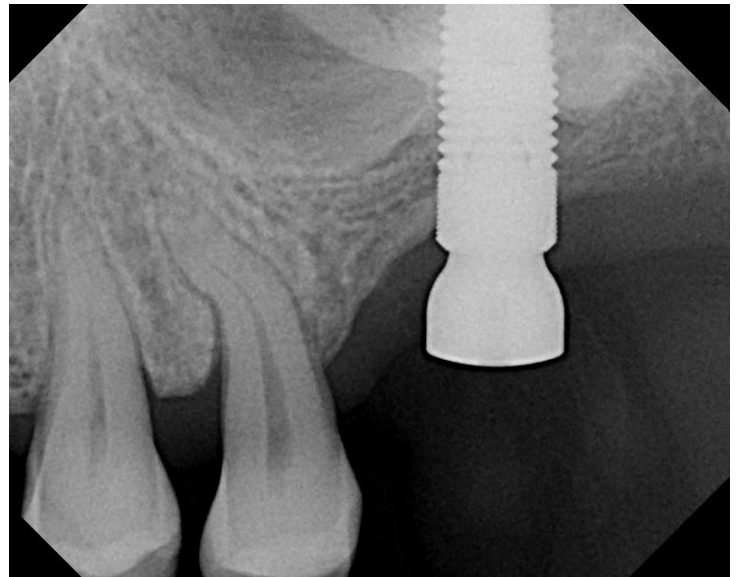
04/01/2010 Steiner Sinus Lift initial grafting.



04/01/2010 Steiner Sinus Lift complete.



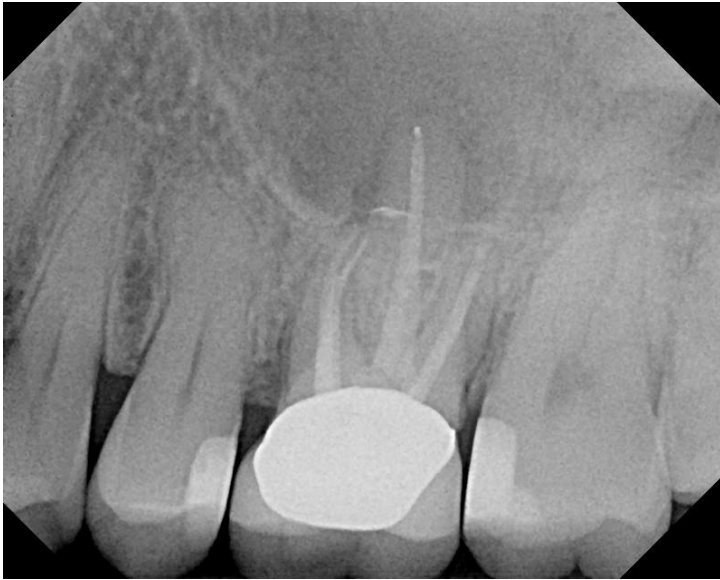04/01/2010 Steiner Sinus Lift complete with implant.



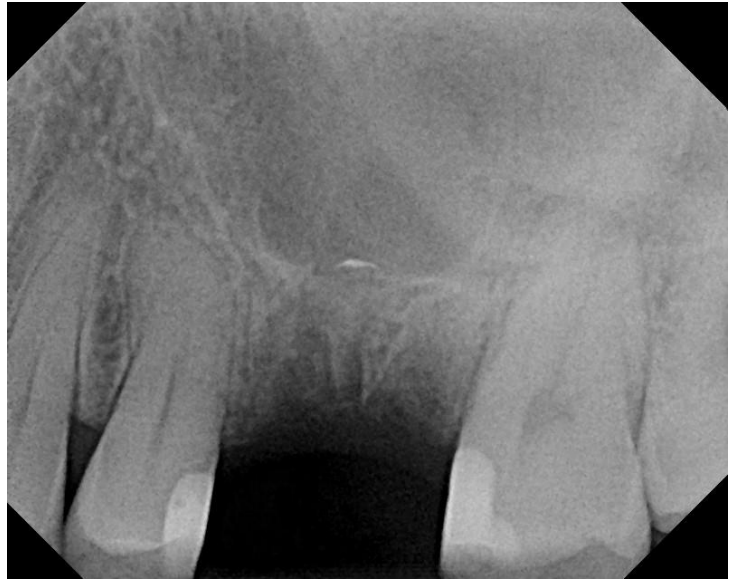07/06/2010 Healing abutment placed referred for restoration

ID: Zum

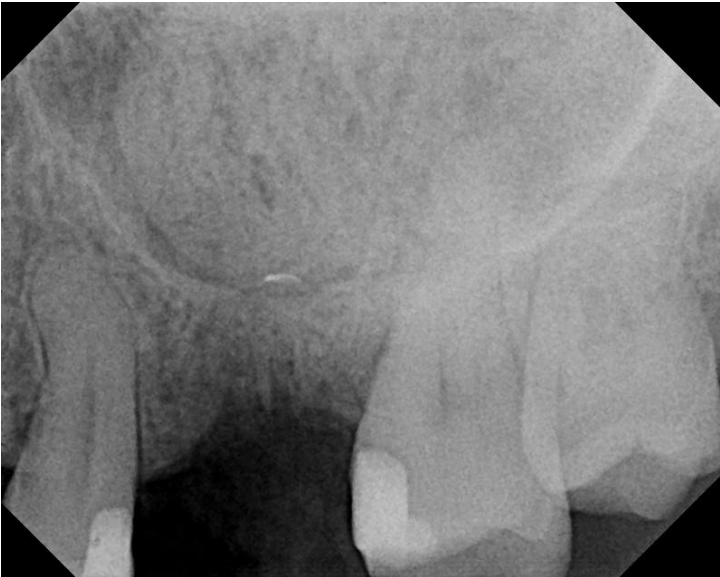#12



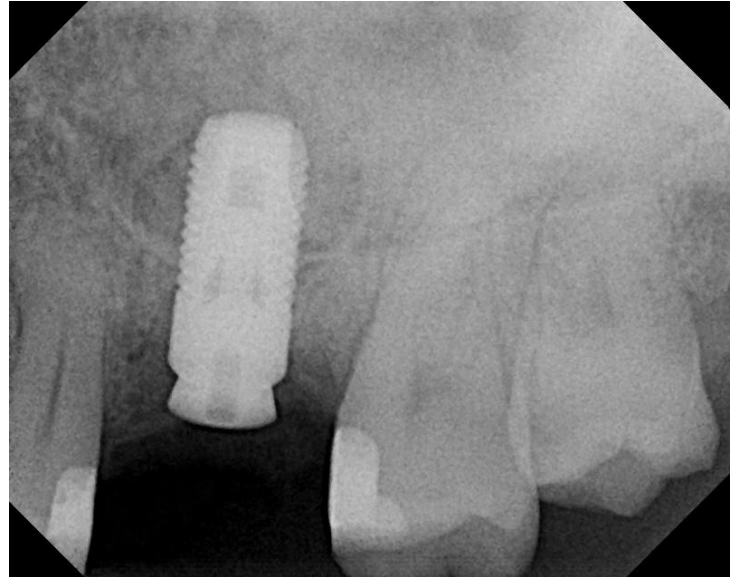08/05/2010 Pre op



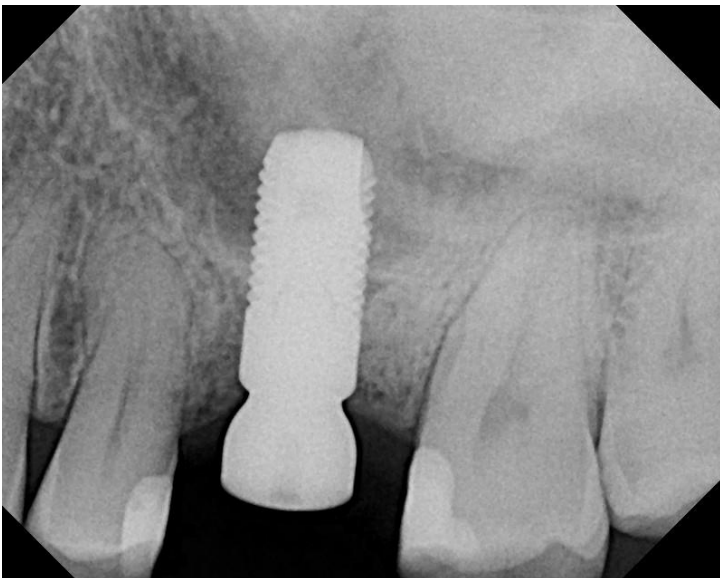
04/15/2010 #14 extracted and grafted with Socket Graft



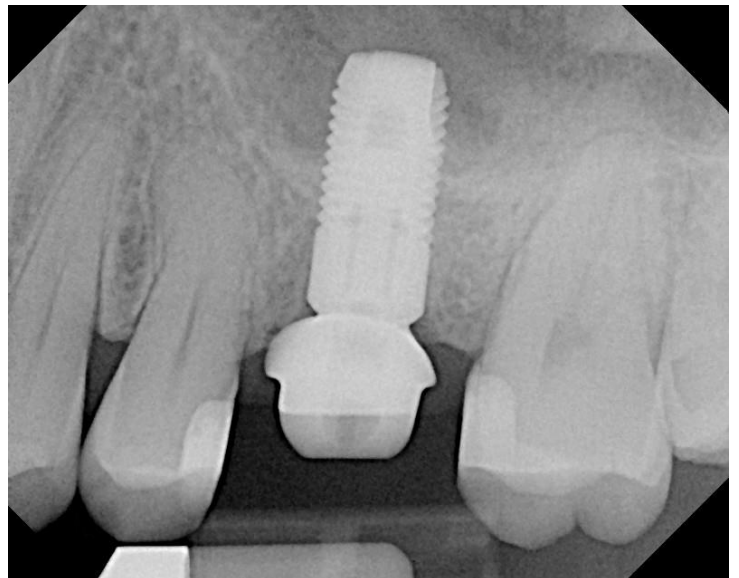
08/05/2010 Steiner Sinus Lift complete



08/05/2010 Steiner Sinus Lift complete with implant.



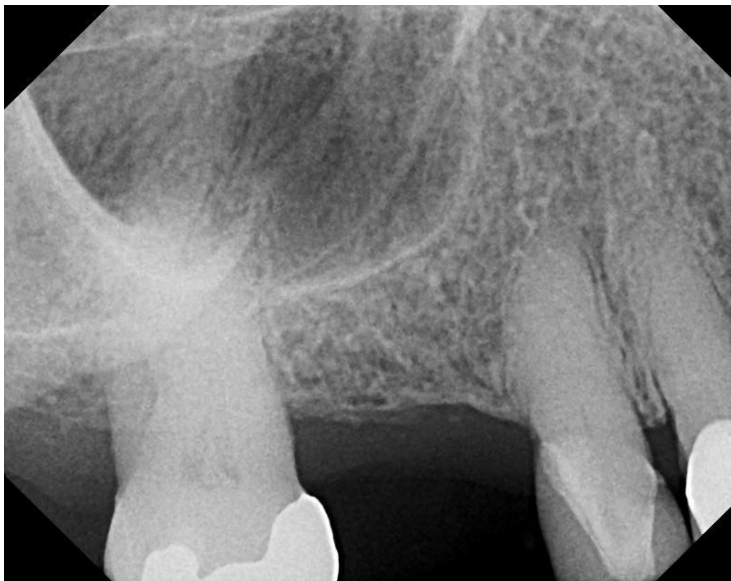
Healing abutment placed



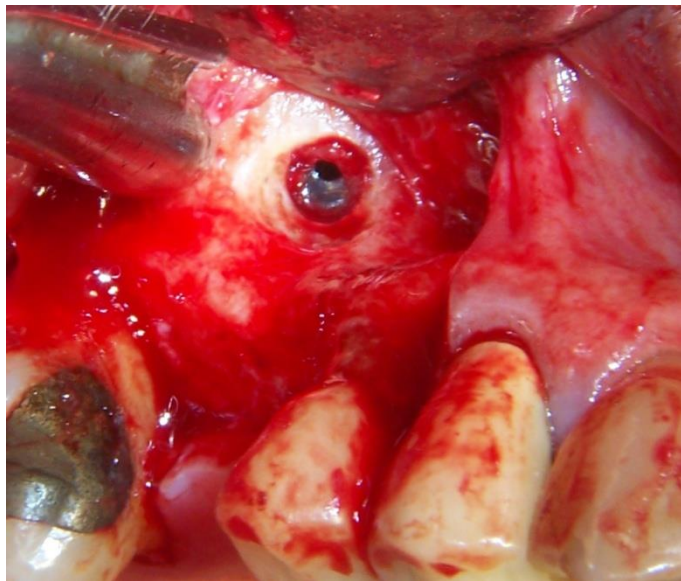
05/15/12 restored

ID: Killion C

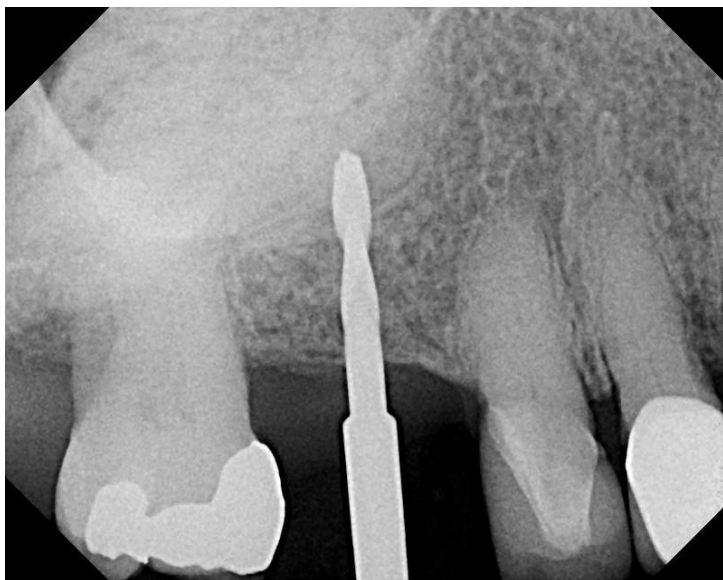#13



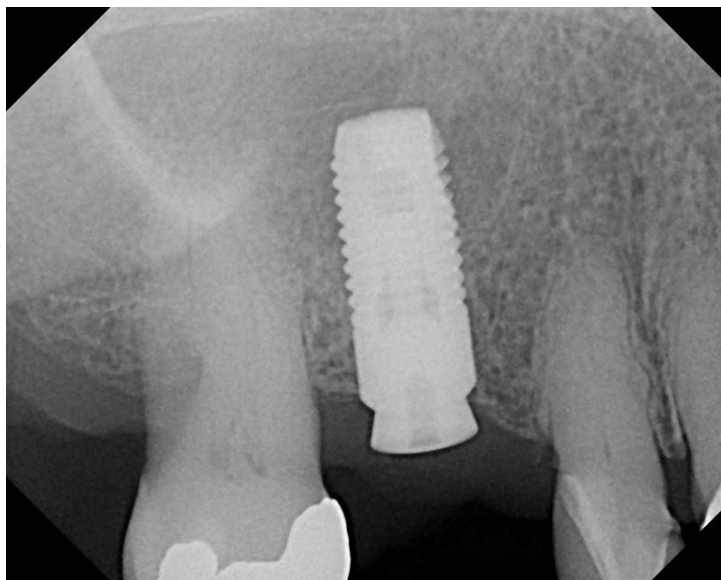
04/27/2010 pre op



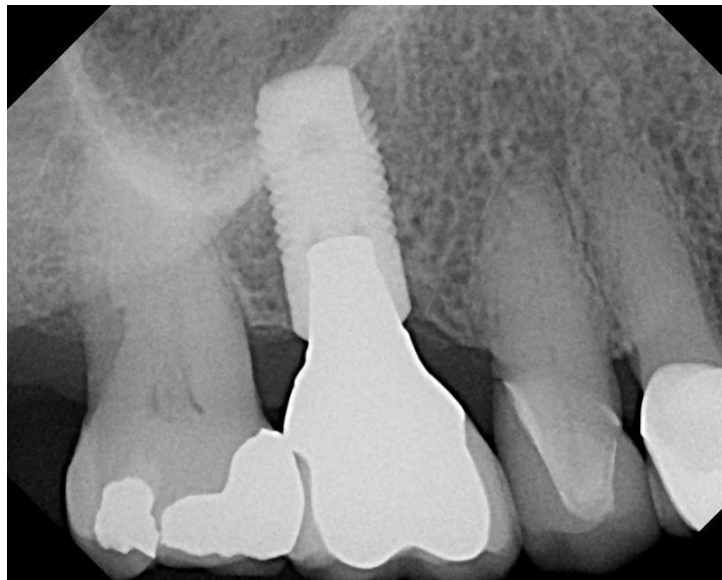04/27/2010 Sinus membrane perforation



04/27/2010 Steiner Sinus complete with pilot drill



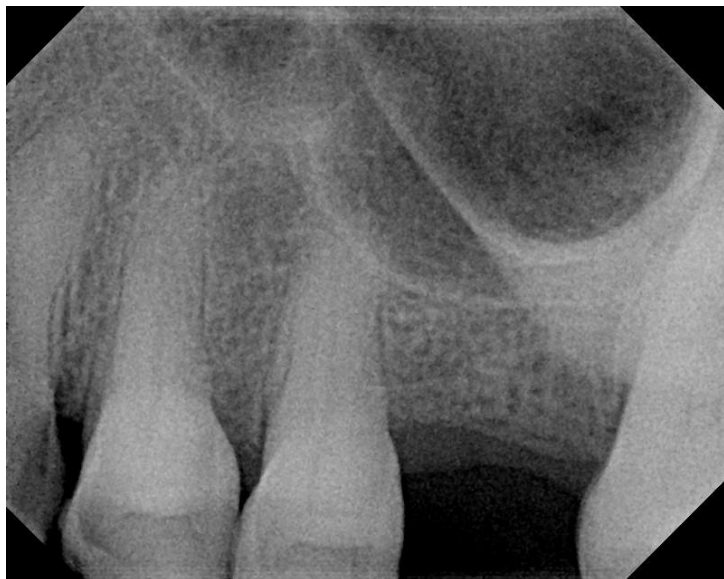04/27/2010 Steiner Sinus Lift complete with implant



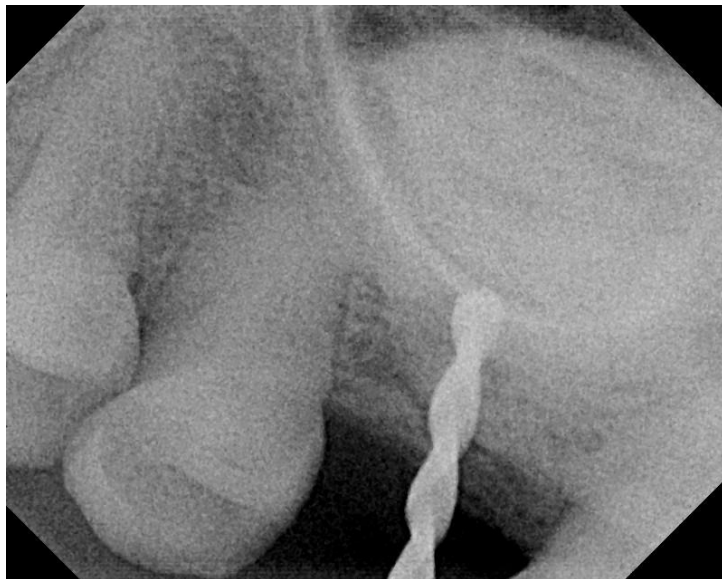03/04/2012 Implant restored

ID: Kell

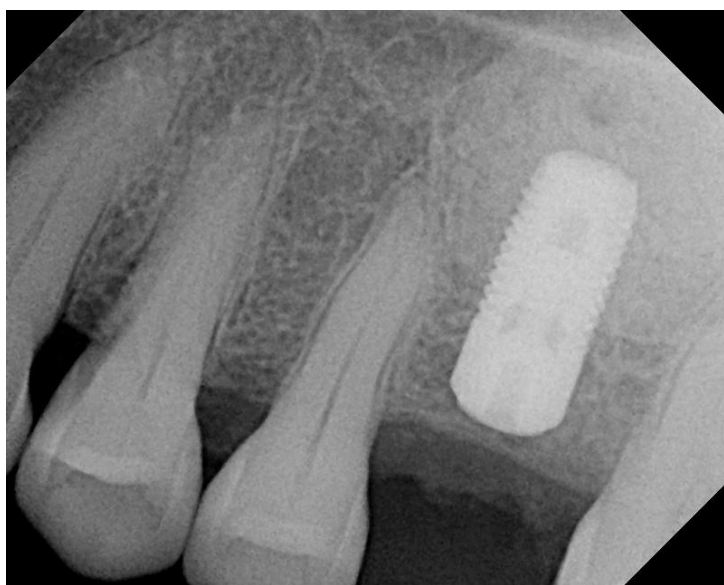
#14



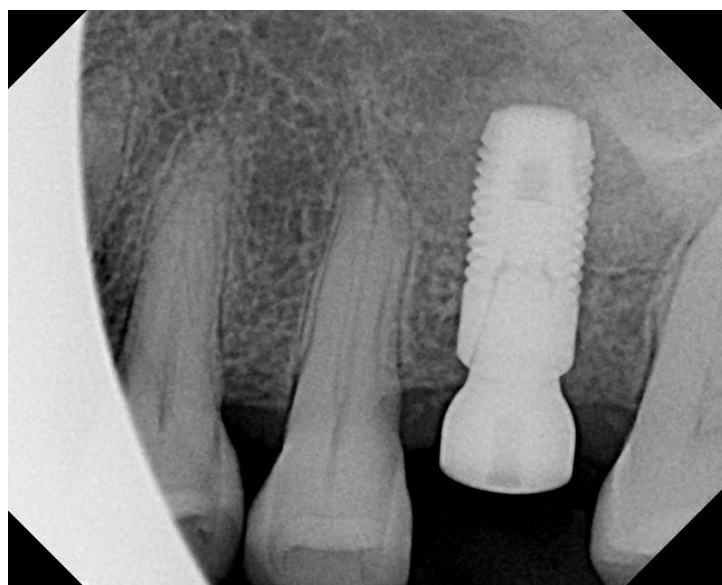Pre op



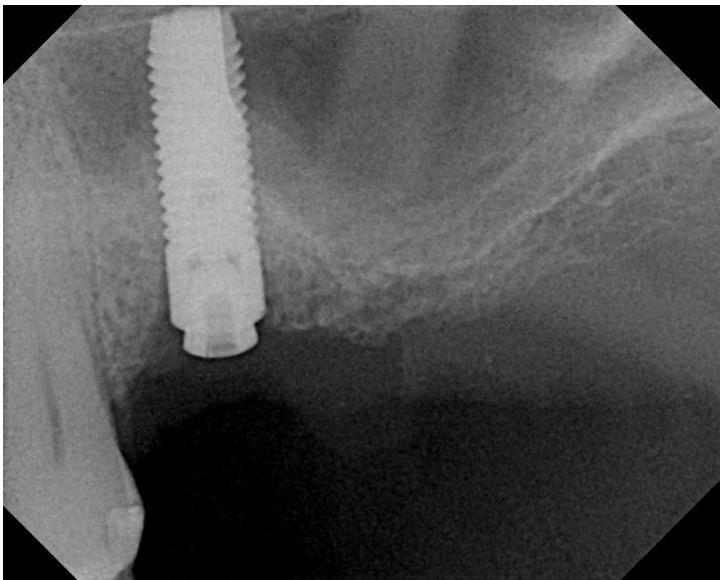
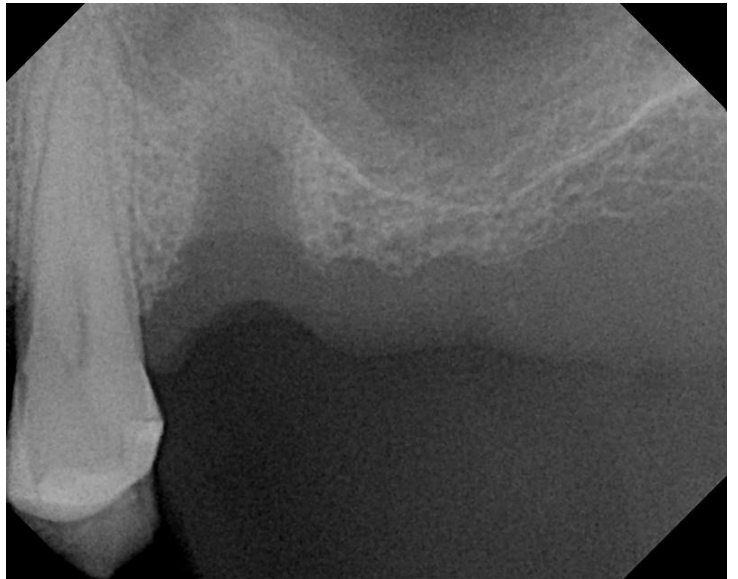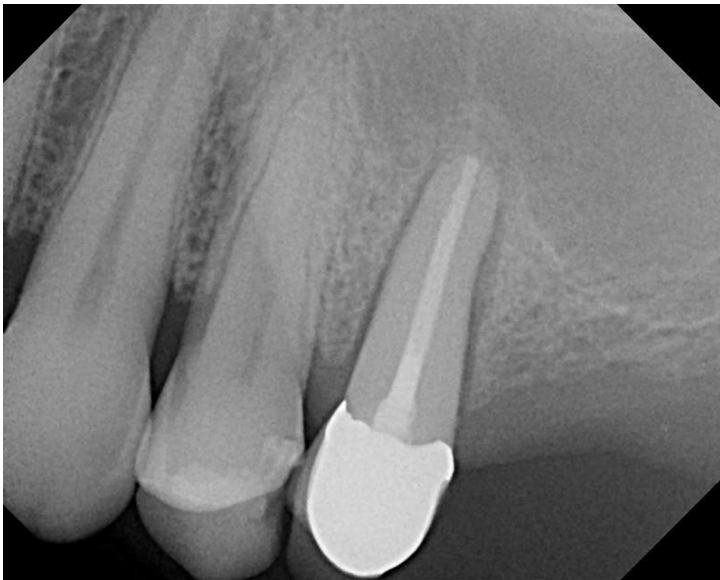05/25/2010 Steiner Sinus Lift Complete with pilot drill.



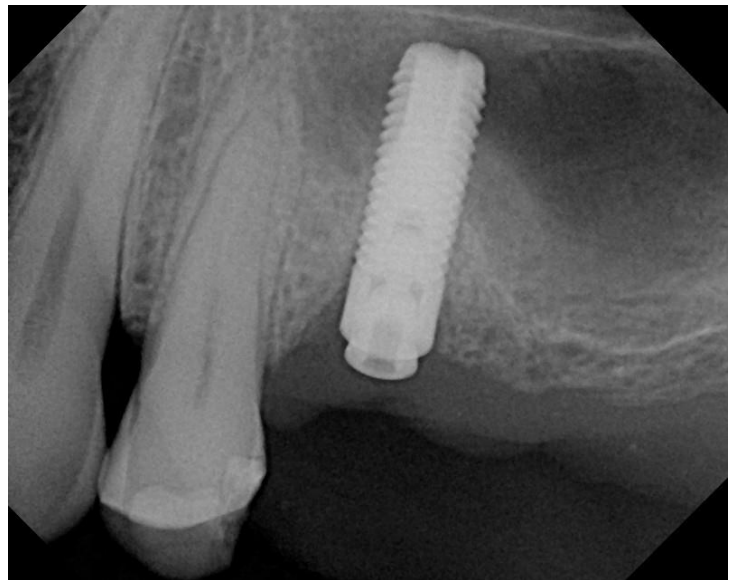
05/25/2010 Steiner Sinus Lift Complete with implant



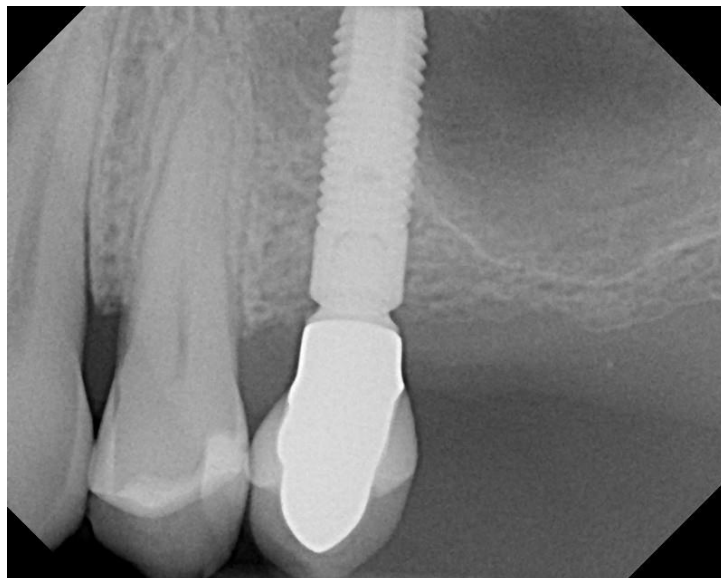09/14/2010 Healing abutment referred for restoration.



05/26/2010 Steiner Sinus Lift



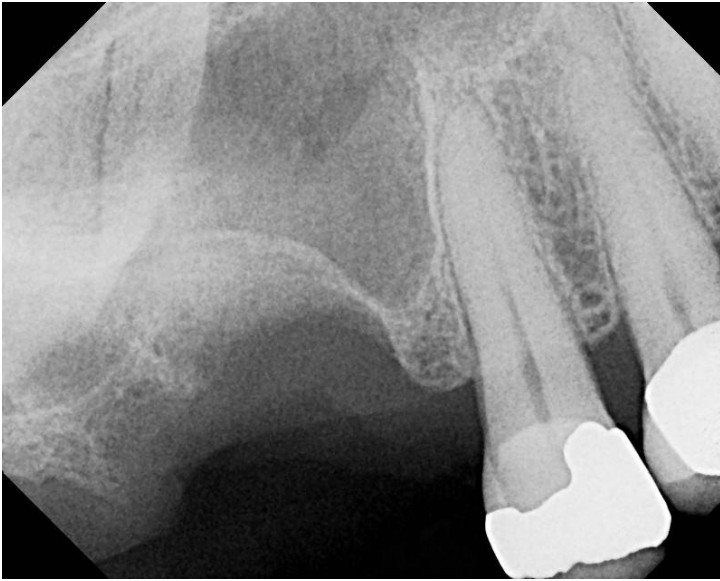
08/01/2010 Healing abutment appointment referred for restorations



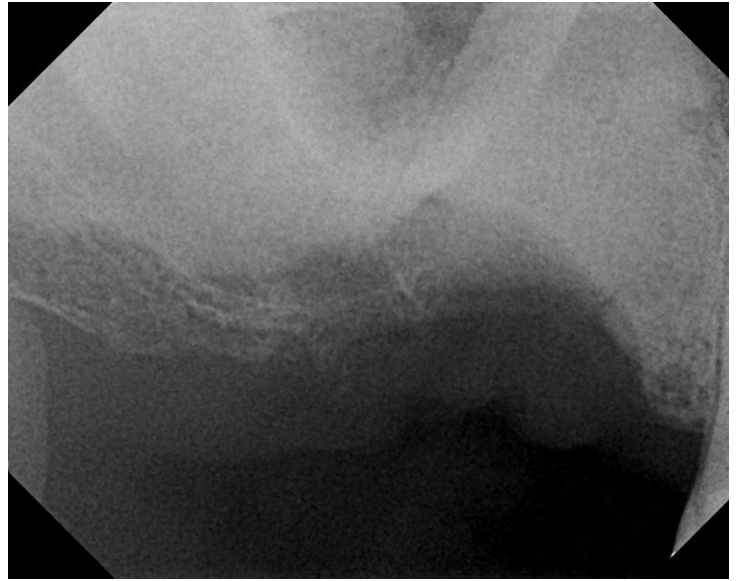03/13/2011 Restored

ID: Fla

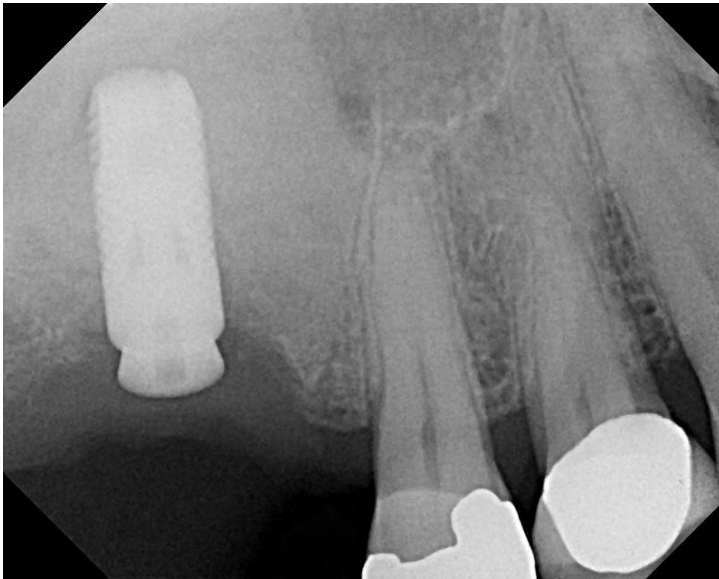
#16



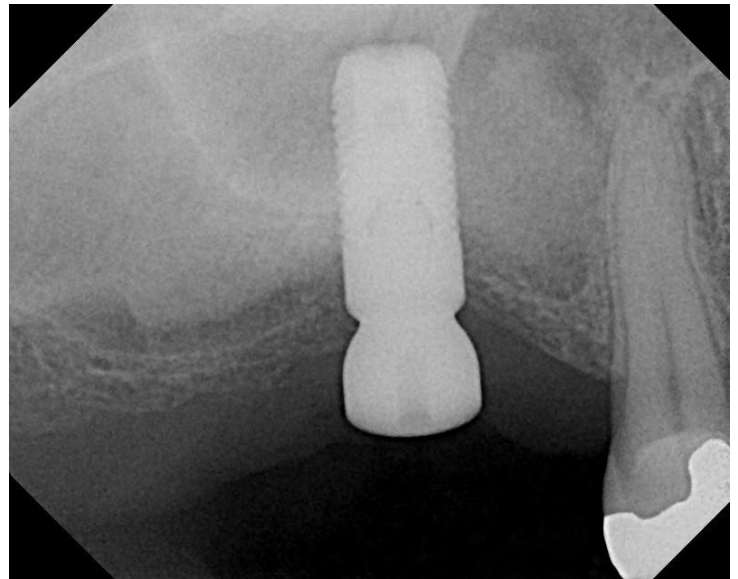
Pre op



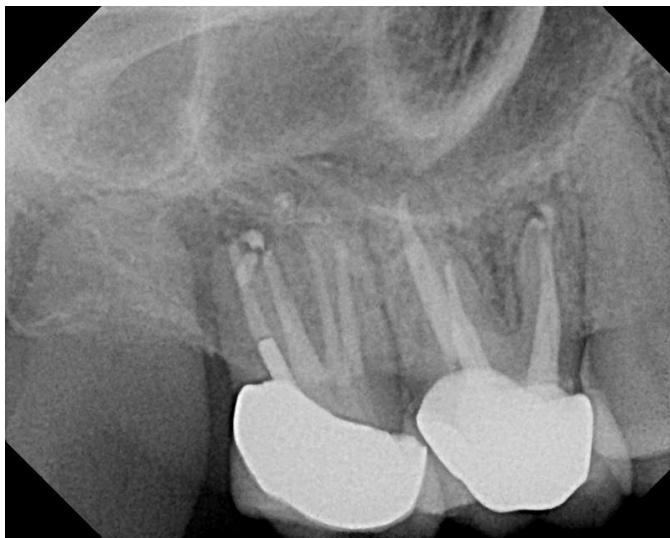
06/10/2010 Steiner Sinus Lift complete



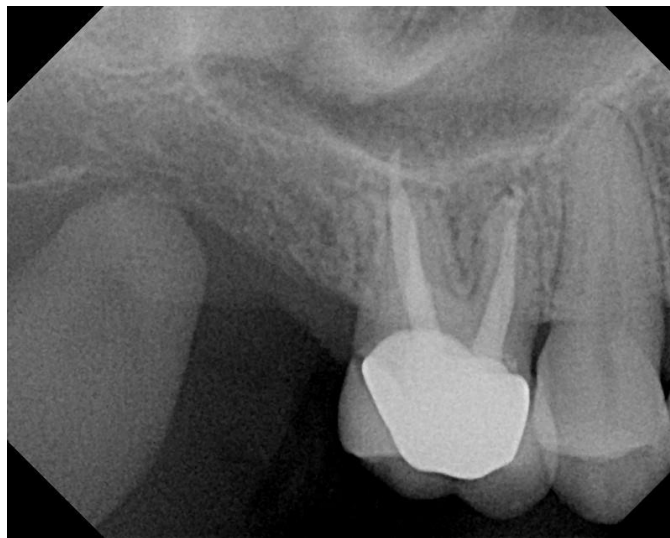06/10/2010 implant placed



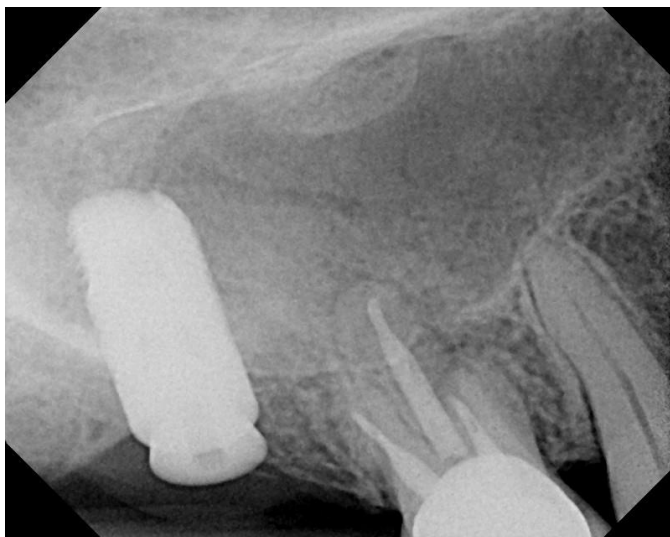
11/08-2011 healing abutment placed and patient referred for restoration.



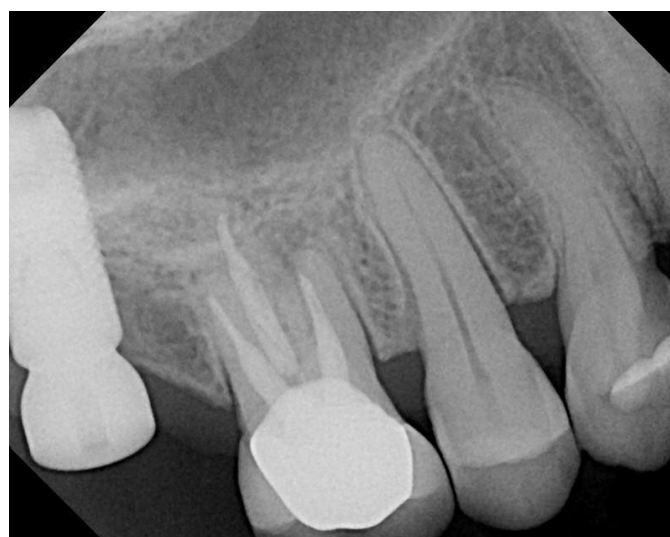06/10/2010 Failing #2 extracted



Sinus lift pre op and grafted with Socket Graft Putty

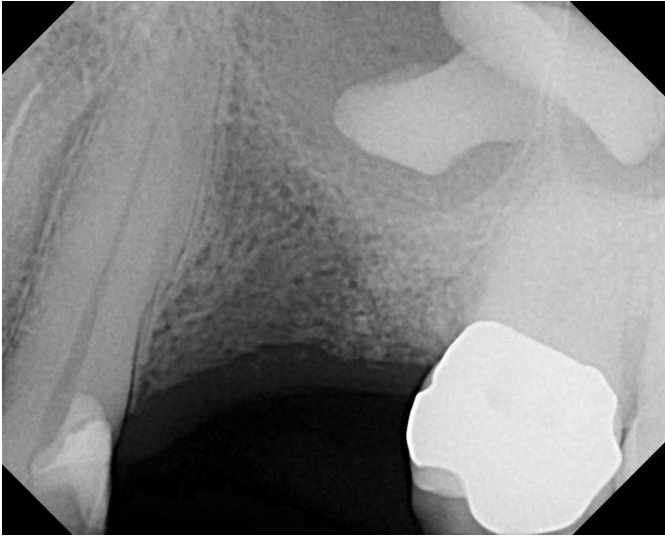


07/25/2010 Steiner Sinus Lift and implant placement

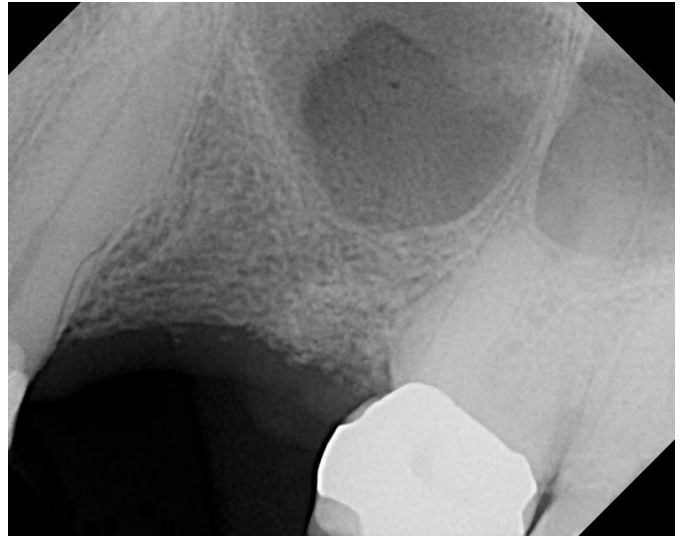

10/13/2010 Healing abutment placed

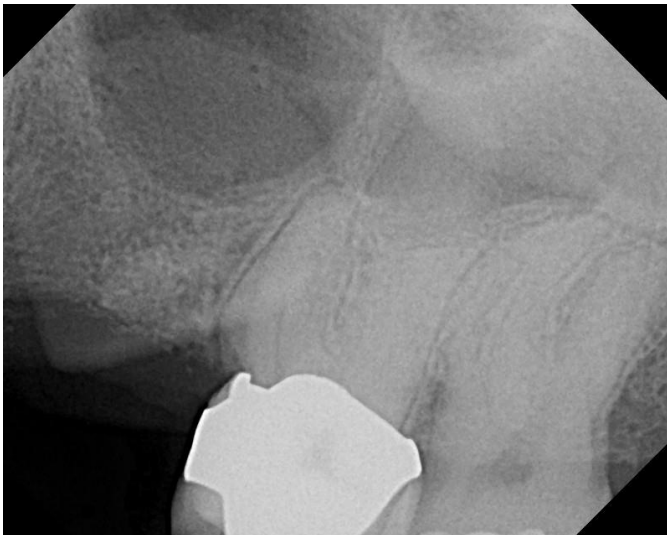During the sinus augmentation the distal buccal root had a periapical lesion that perforated the sinus. The apex of the root was removed during the sinus augmentation.



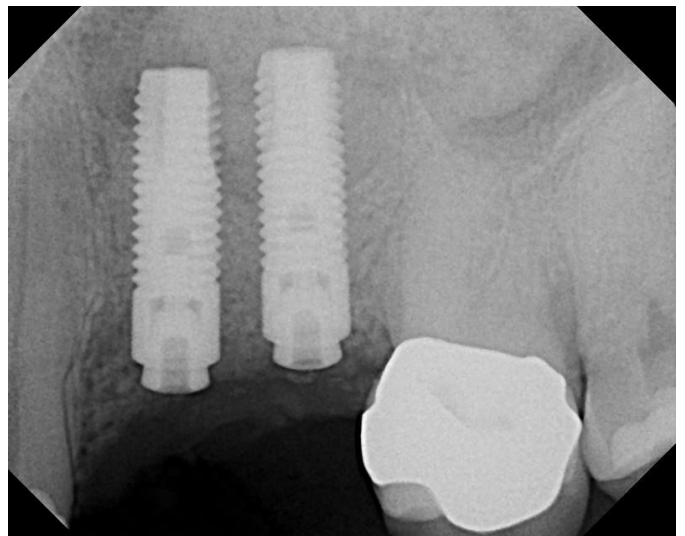
Pre op pneumatized sinus with foreign objects.



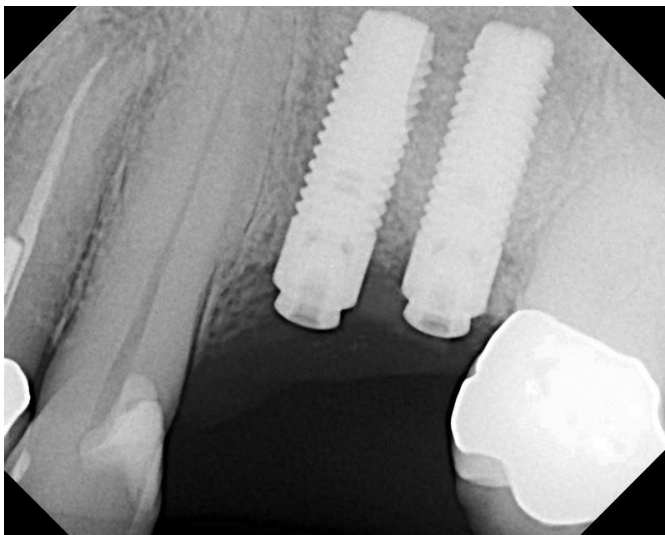
6/23/10 foreign objects removed.



6/23/10 Osteotomy bedded with Ridge Graft™ and covered with OsseoConduct cortical plate

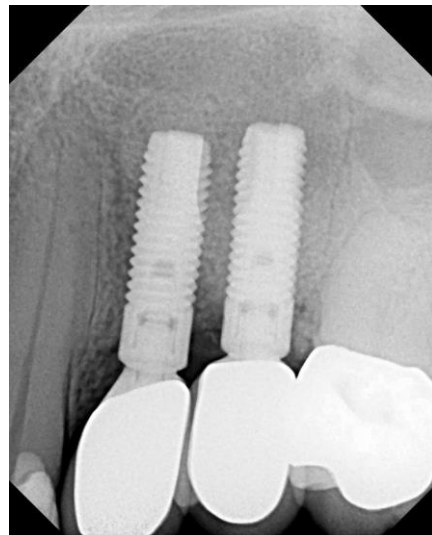

9/15/10 Steiner Sinus Lift and implant placement

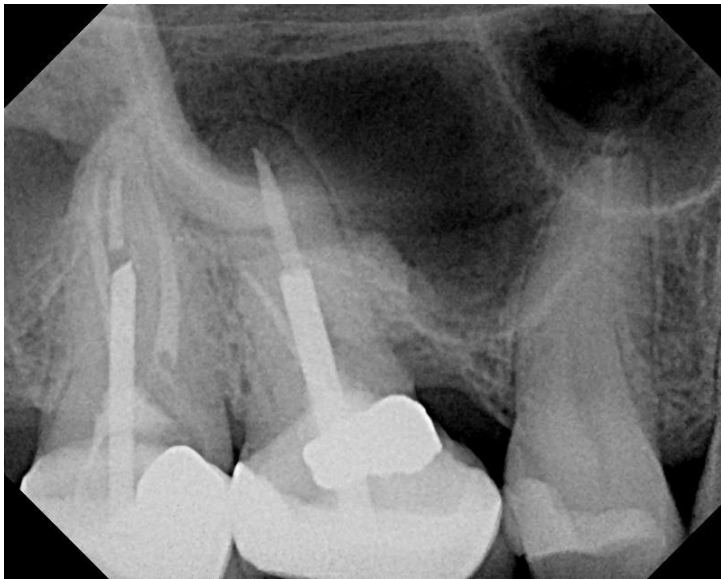


10/6/10 healing abutments placed

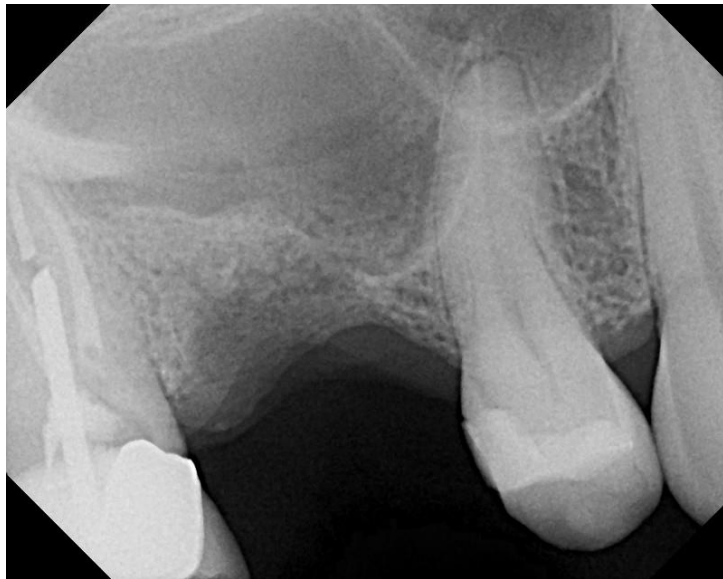The foreign objects were encased in granulation tissue and a biopsy identified the objects as supernumerary teeth.



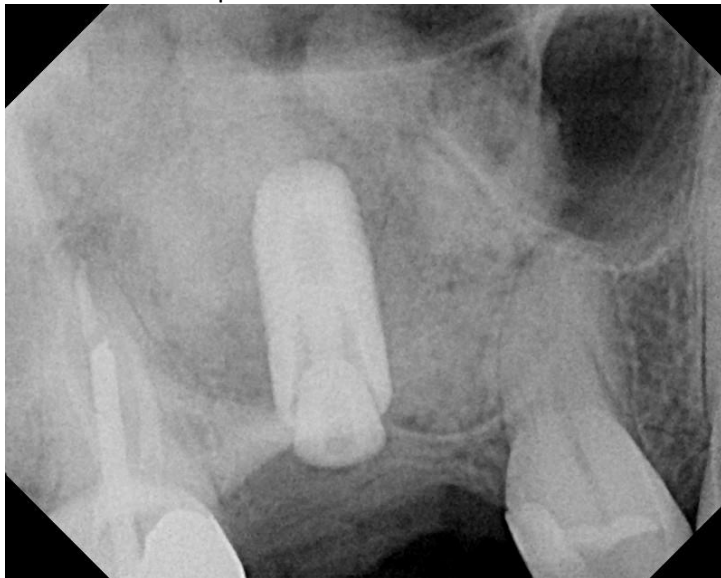Restored



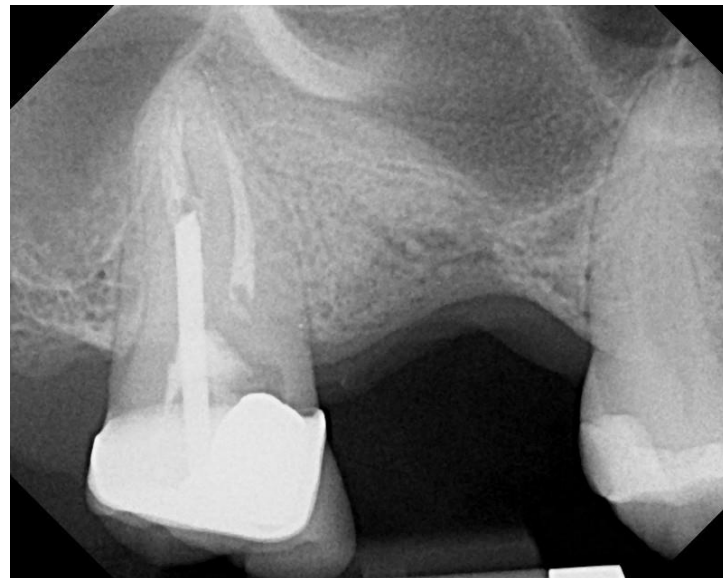07/06/2010 Tooth #3 had a root amputation with an allograft placed in the mesial buccal root extraction site years before and now a periodontal lesion has formed on the mesial surface. Because of the allograft in the site, regenerative periodontal therapy is not possible over an allograft therefore, the tooth was determined hopeless.



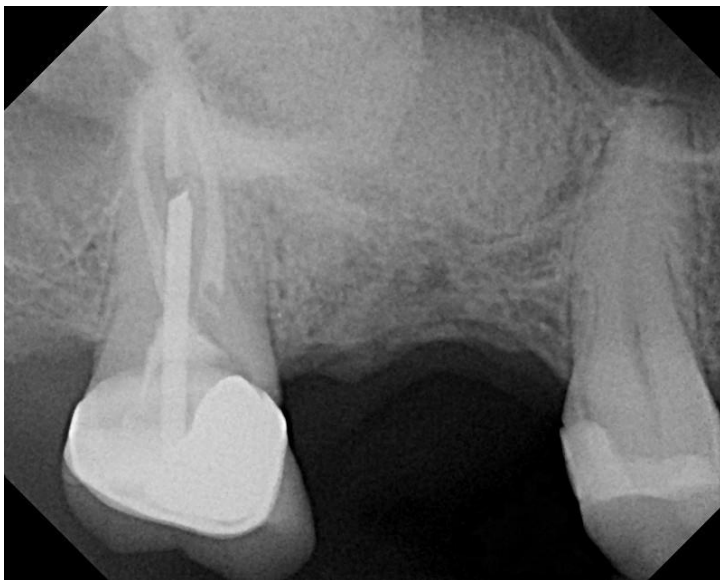Tooth #3 was extracted and grafted with Socket Graft.



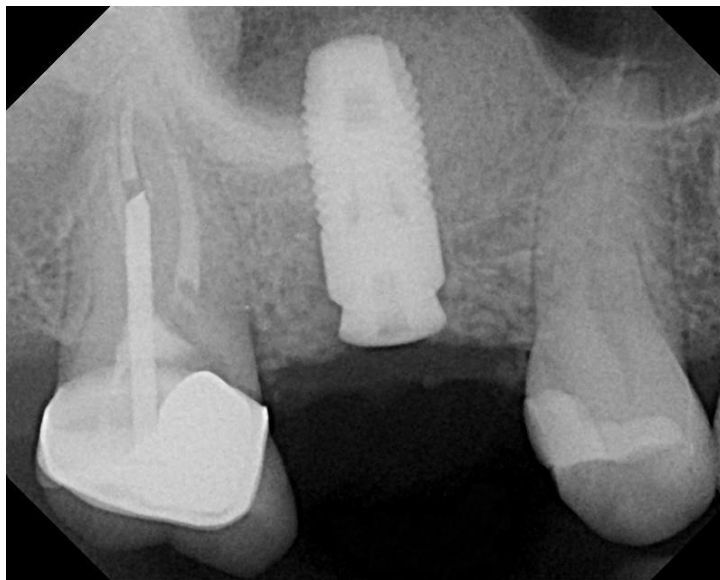04/04/2011 The Steiner Sinus Lift was performed but when the osteotomy was performed in the area of the allograft, the bone broke apart and had no bone remaining to contact the implant. The implant was floated in Snus Graft™ while in the sinus but the implant failed to integrate. The implant was removed and the site was grafted with Socket Graft.



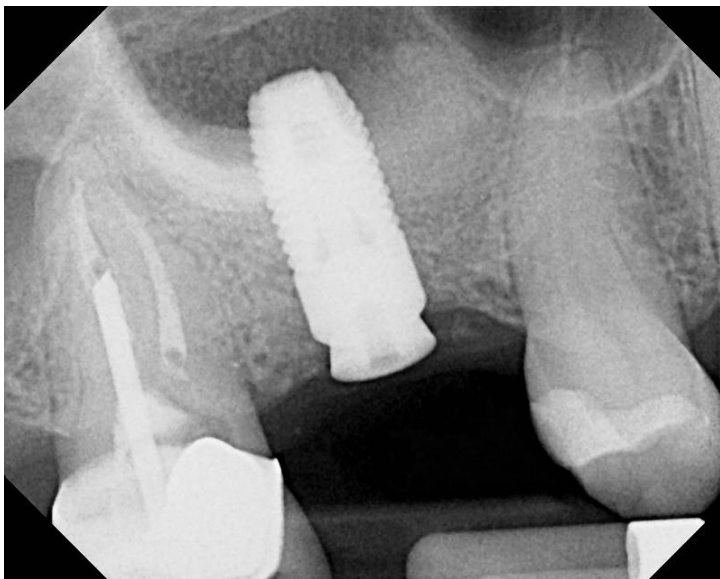
Pre op after implant removal



10/12/2011 Sinus re-grafted with Sinus Graft™.



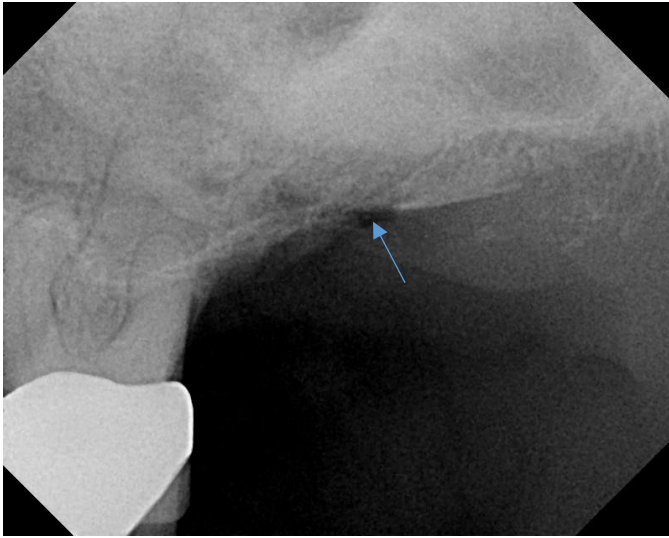
10/12/2011 implant placement same time it was grafted.



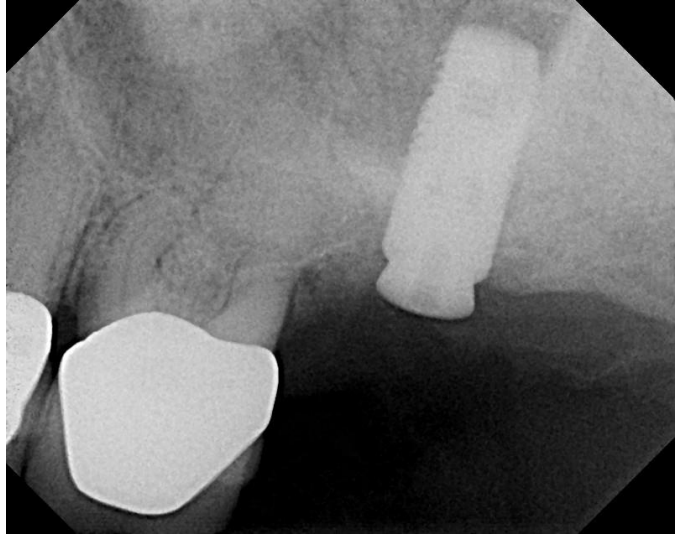Healing abutment appointment with patient referred for restoration.

ID: Digi

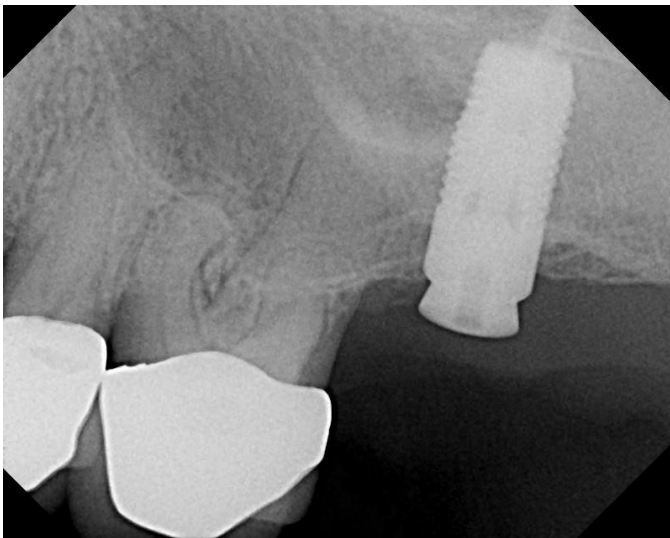
#20



07/18/2010 Due to minimal bone, the osteotomy was made through the crest as noted by arrow on the radiograph. with sinus filled with Sinus Graft



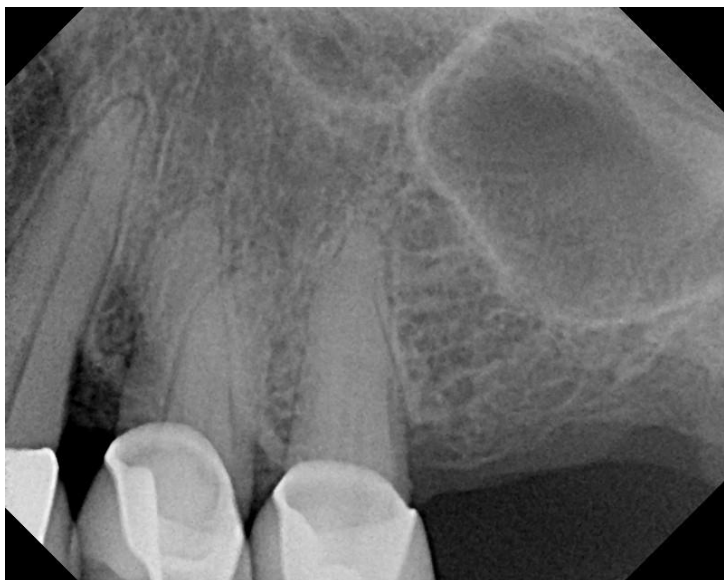07/18/2010 Steiner Sinus Lift complete



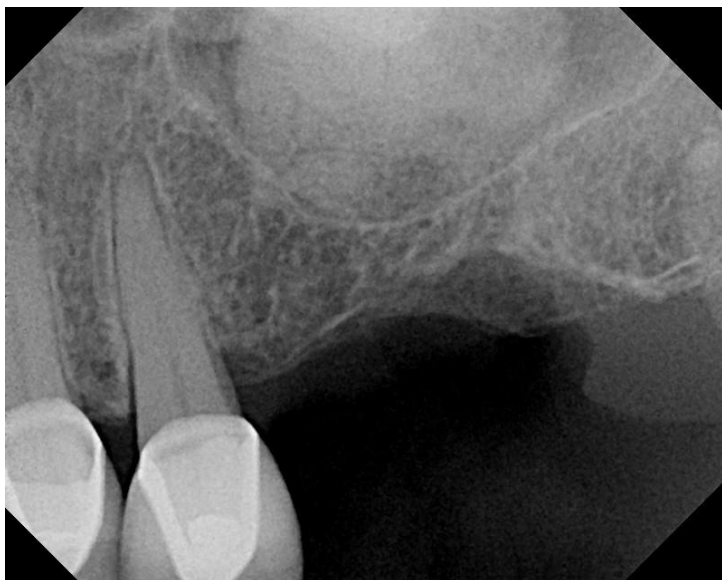10/28/10 Healing abutment appointment

ID: Hed

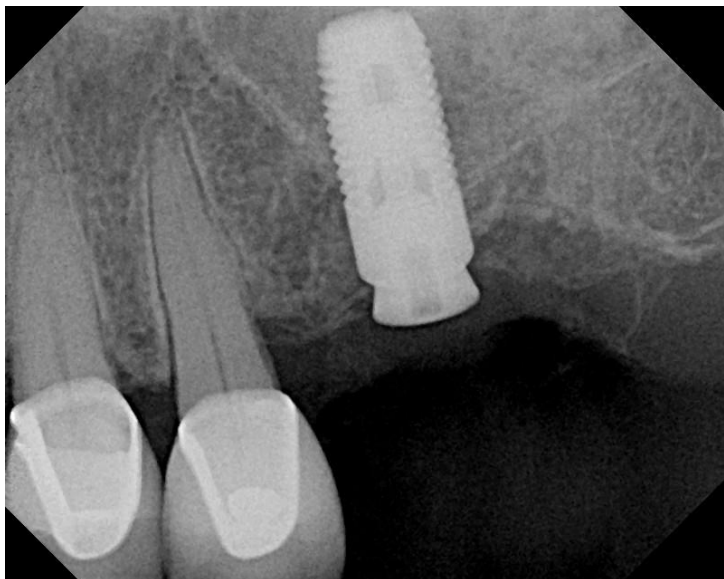
#21



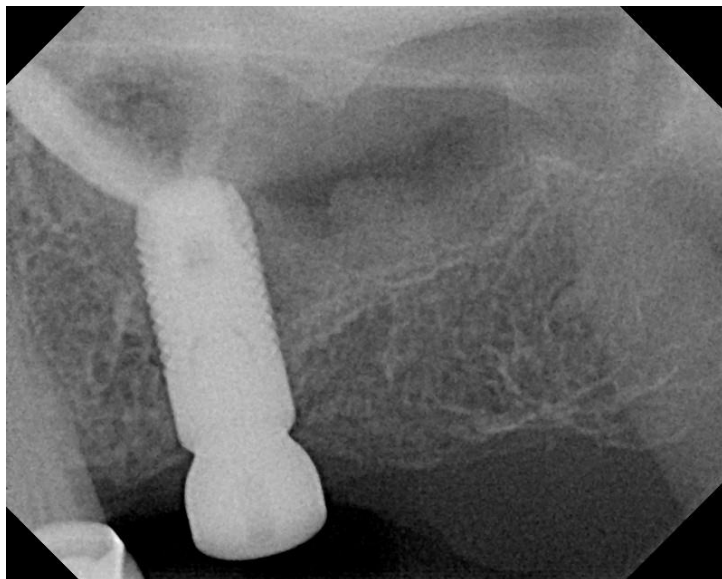
Pre op



08/03/2010 Steiner Sinus Lift complete.



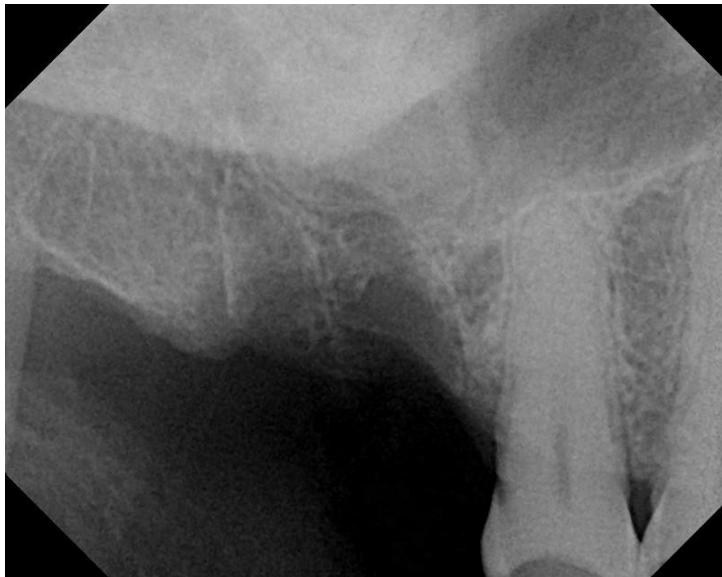08/03/2010 implant placed



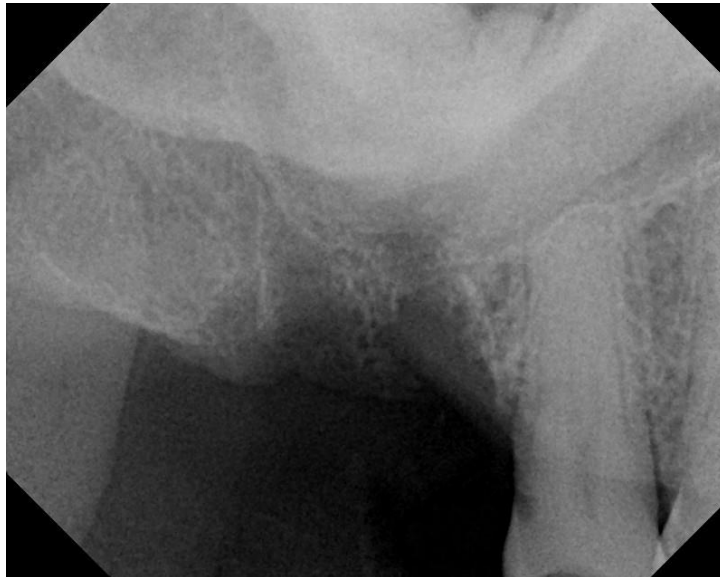11/23/2010 Healing abutment placed referred for restoration.

ID: Mor

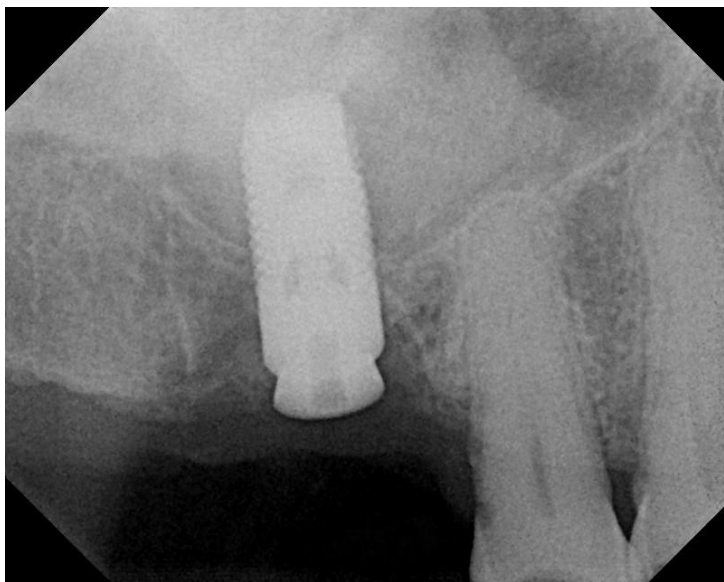
#22



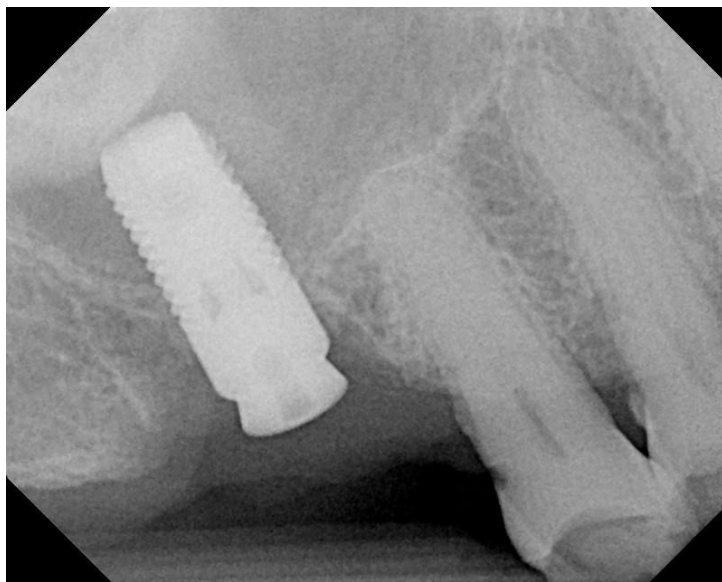
The molar was extracted and not grafted explaining the poor mineralization in the extraction site.



10/12/2010 Steiner Sinus lift complete.

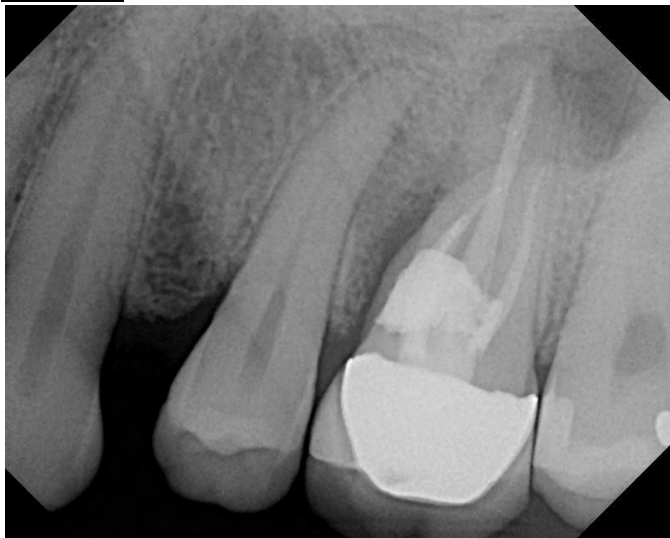

10/12/1020 implant placed.

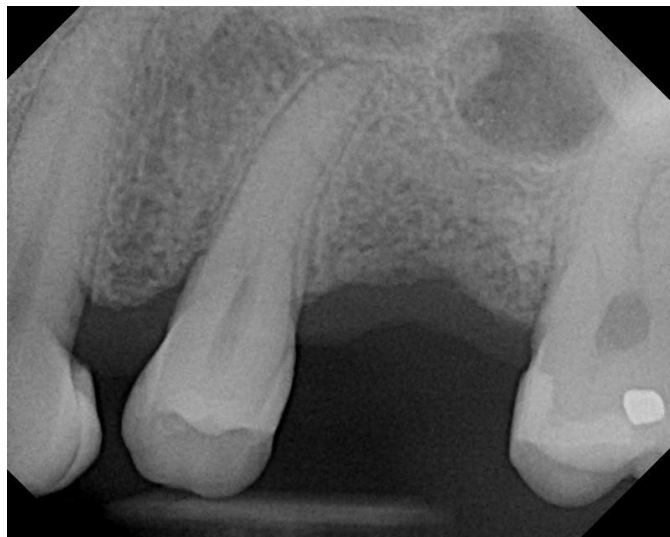

Day of healing abutment placement.

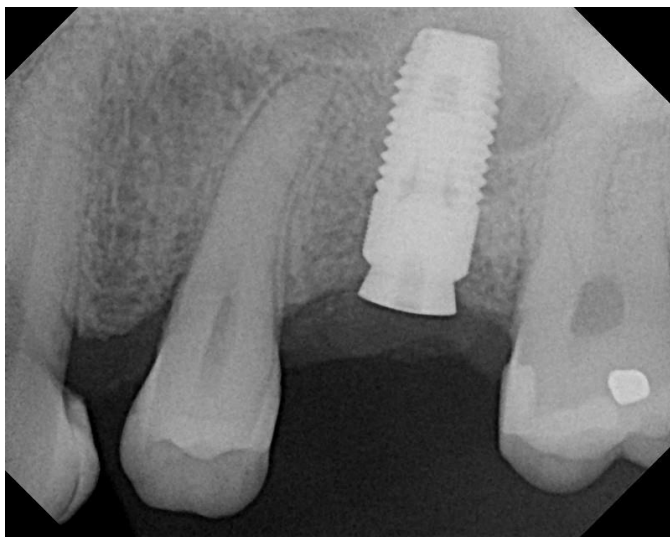ID: ARE #23



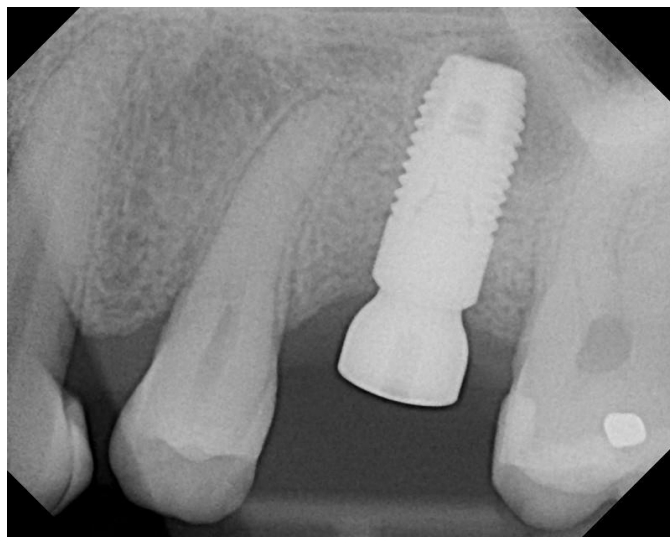
Extracted and grafted with Socket Graft. 11/11/10



Pre op Steiner Sinus Lift and implant 12/22/11



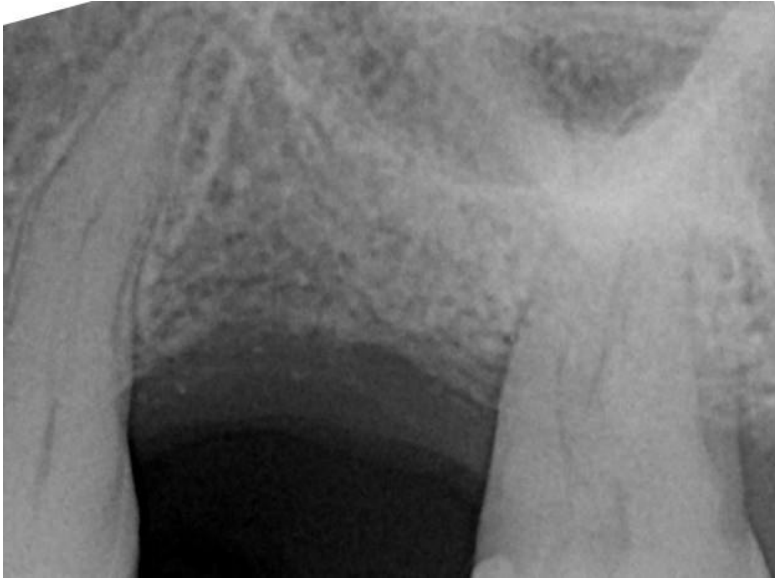
Steiner Sinus Lift and Implant 12/22/11



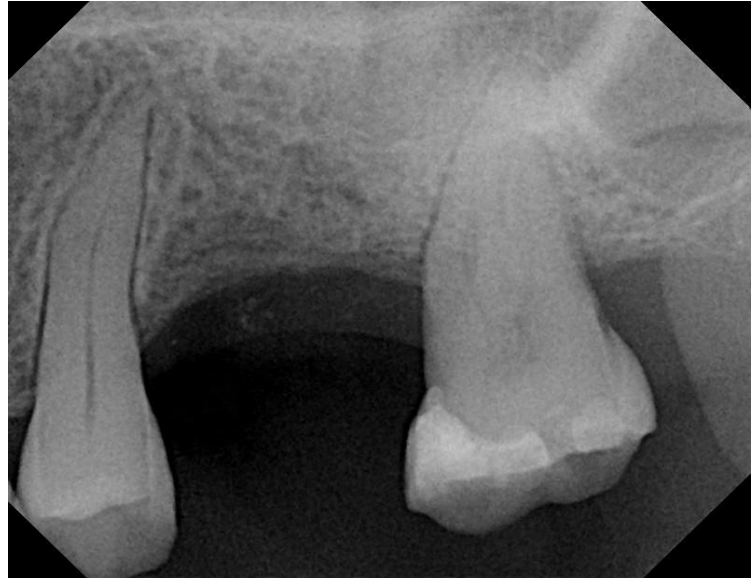Healing abutment 3/13/12 referred for restoration.

ID: Bon

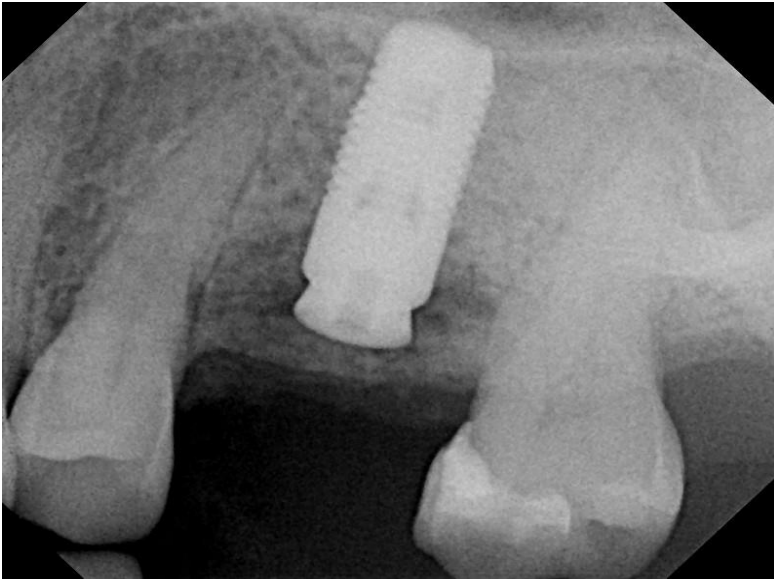
#24



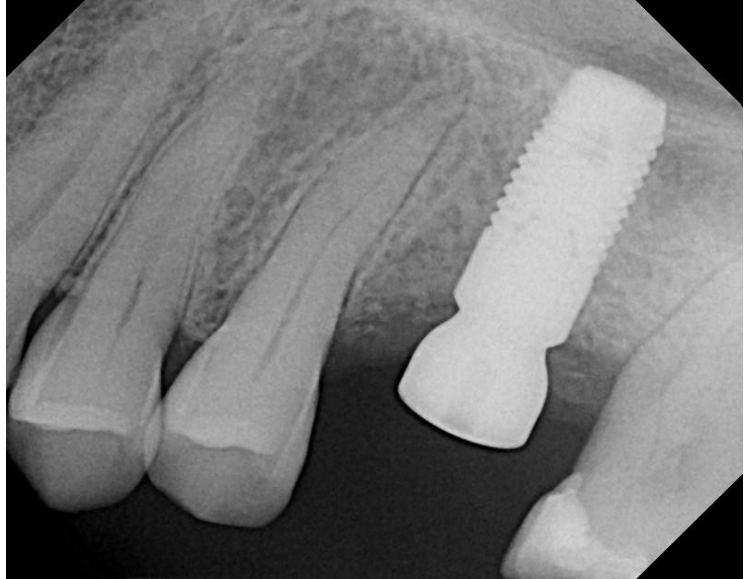
Pre op radiograph



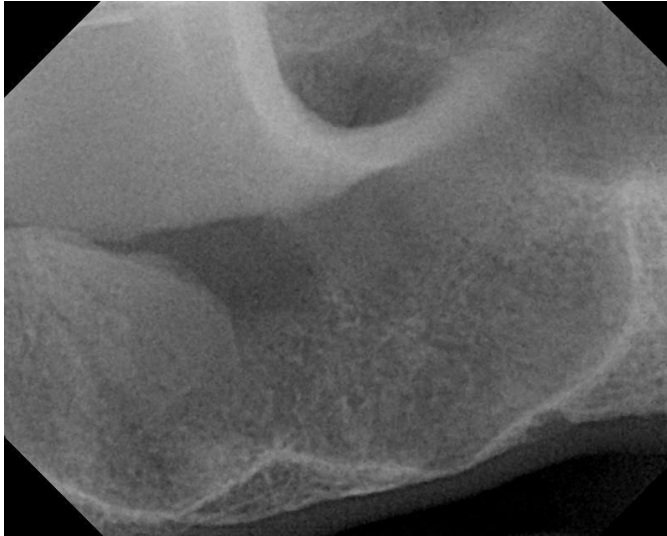11/23/2010 Steiner Sinus Lift complete



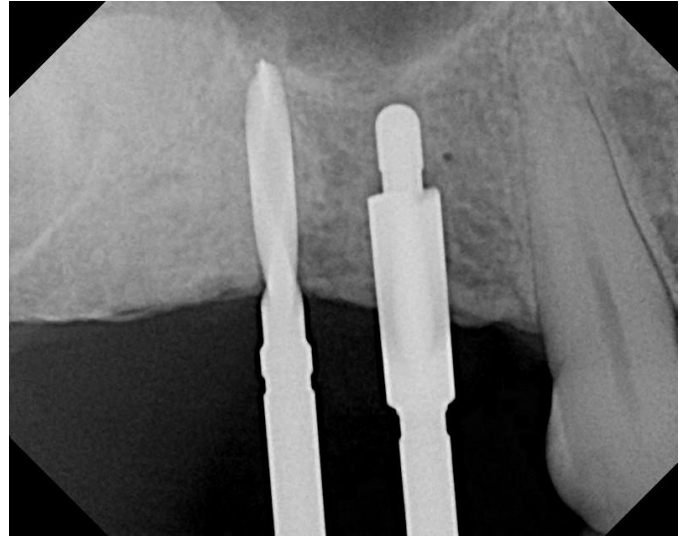
11/23/2010 Implant placed



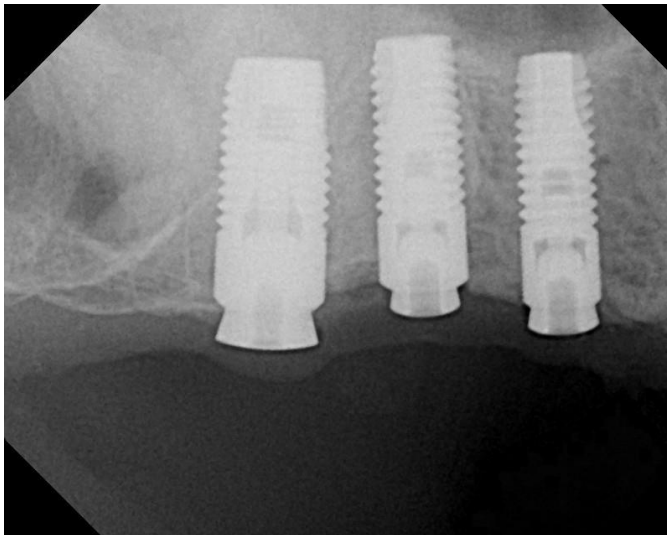
04/26/2011 Healing abutment placed



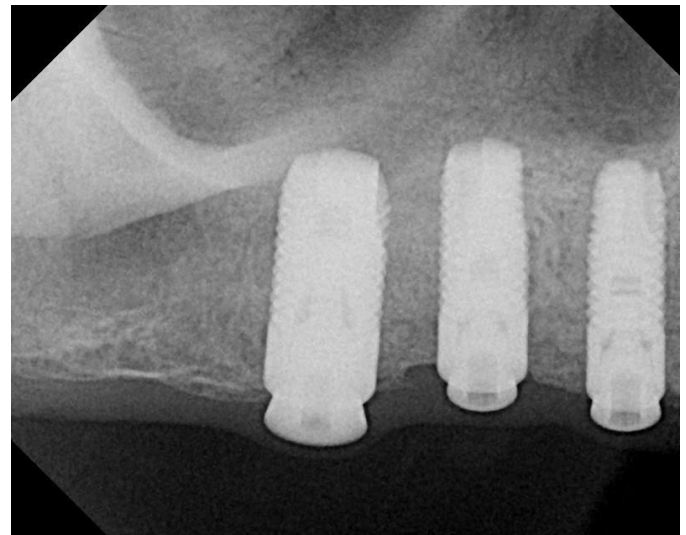
Pre op radiograph shows minimal bone.



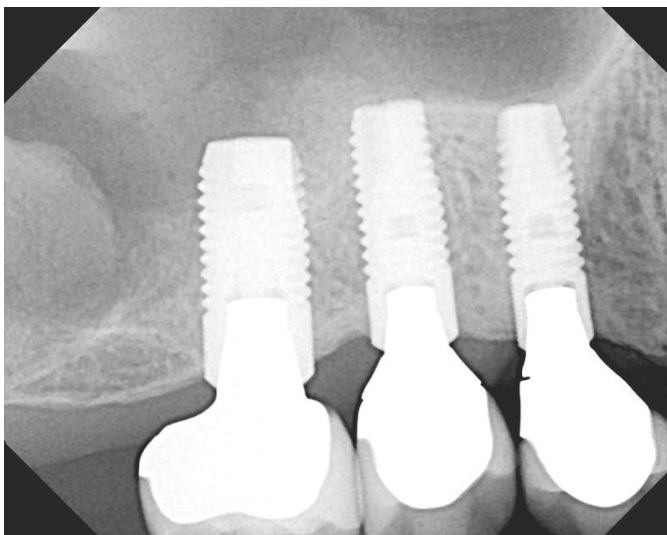
01/05/11 Steiner Sinus lift complete.



01/05/11 Implant 3 and 4 in graft with 1 to 2 mm crestal bone.



04/14/2011 healing abutment appointment.

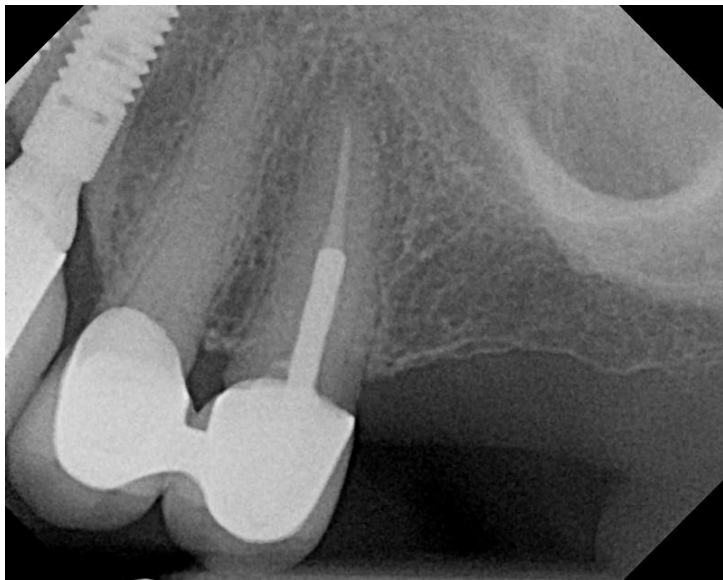


04/24/2012

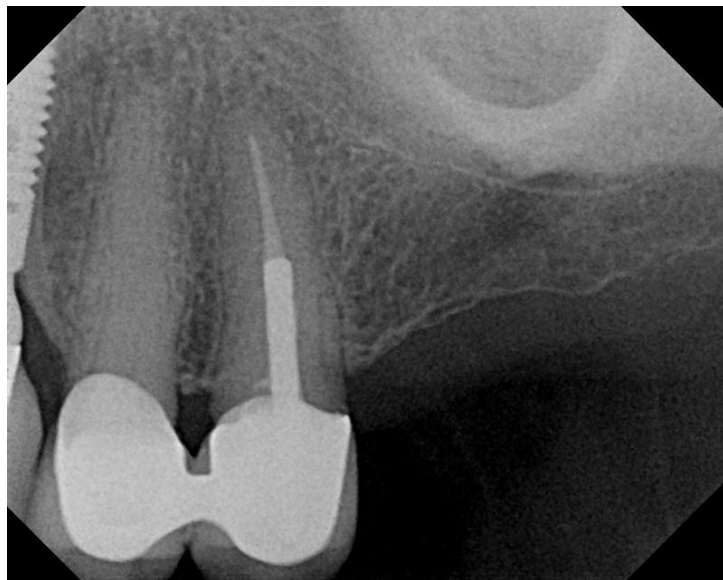
One year post op check. During the sinus augmentation using the Steiner Sinus lift, the sinus membrane tore at first entry. The sinus membrane was dissected off the floor and the walls of the sinus with no effort to maintain membrane over the graft. Sinus Graft™ was injected onto the floor of the sinus and the implants were placed. After 4 months, the healing abutments were placed and the implants were loaded.

ID: Rig

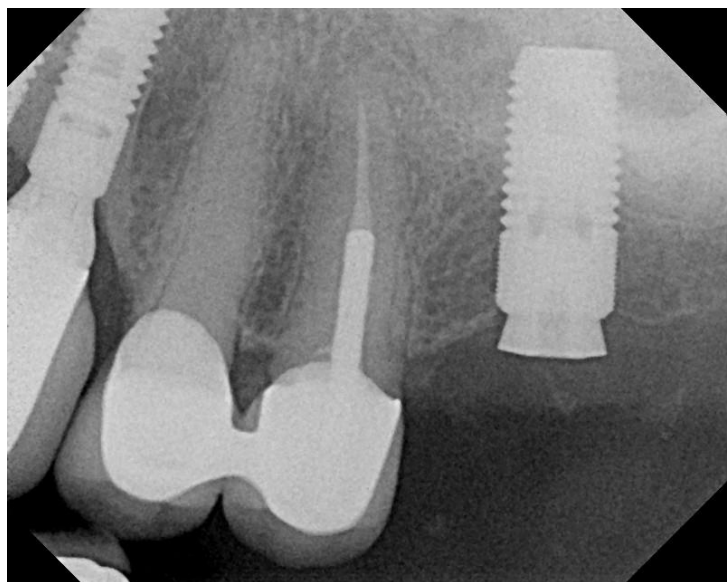
#26



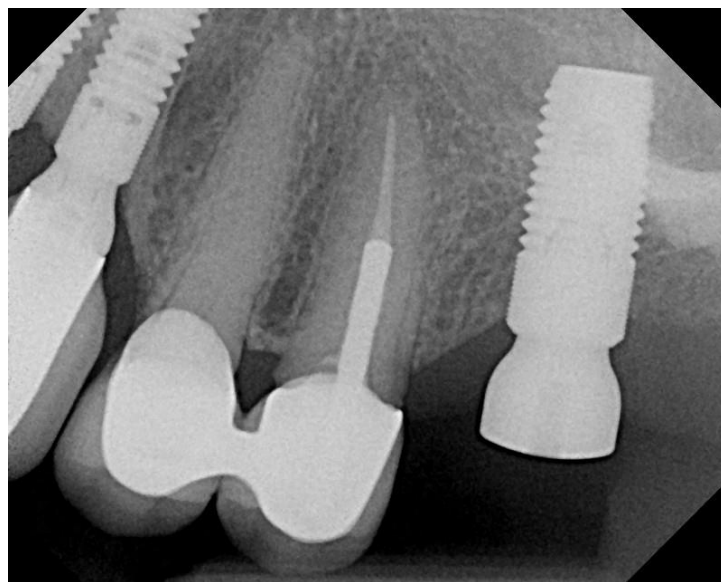
Pre op 01/20/2011



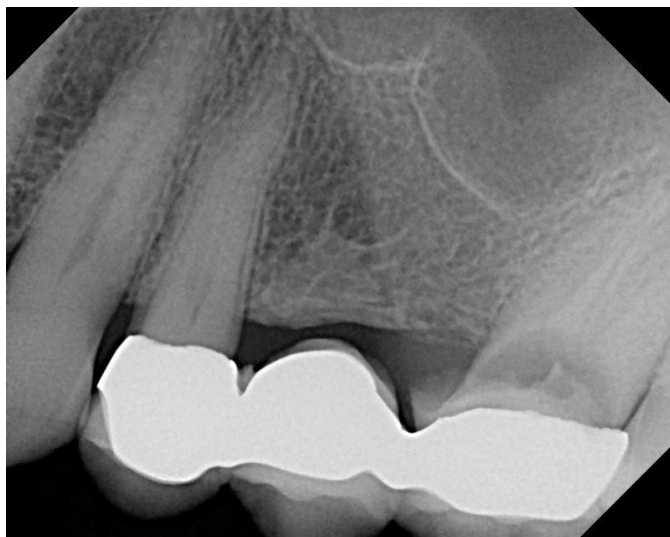01/20/2011 Steiner Sinus Lift complete



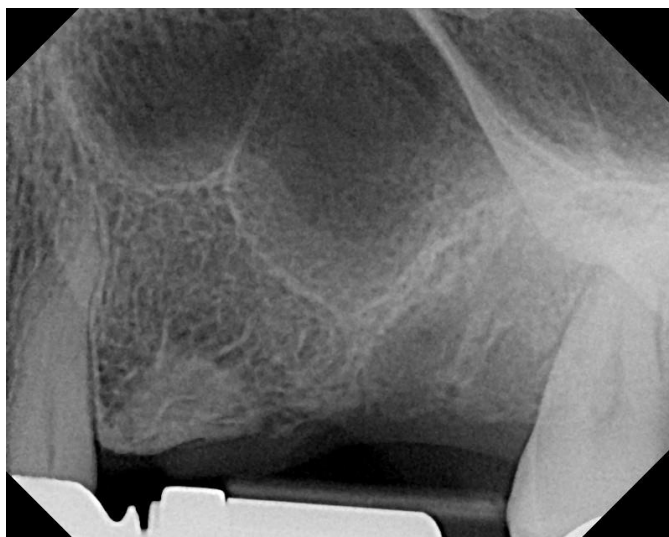01/20/2011 Steiner Sinus Lift with implant



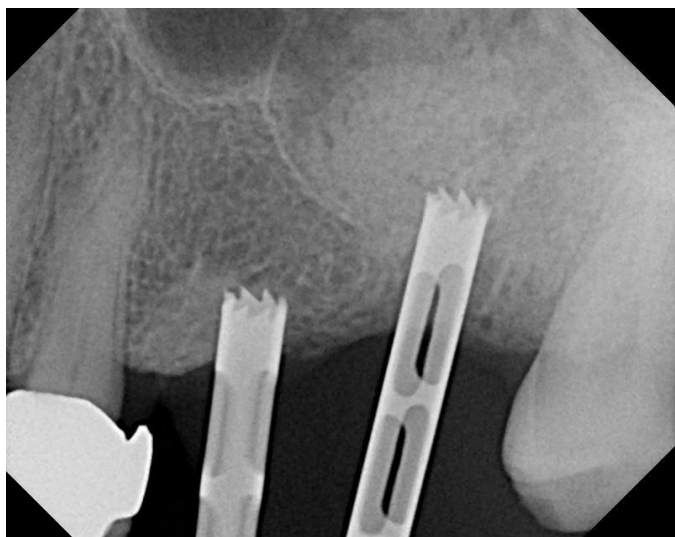05/12/2011 Healing abutment placed and referred for restoration.



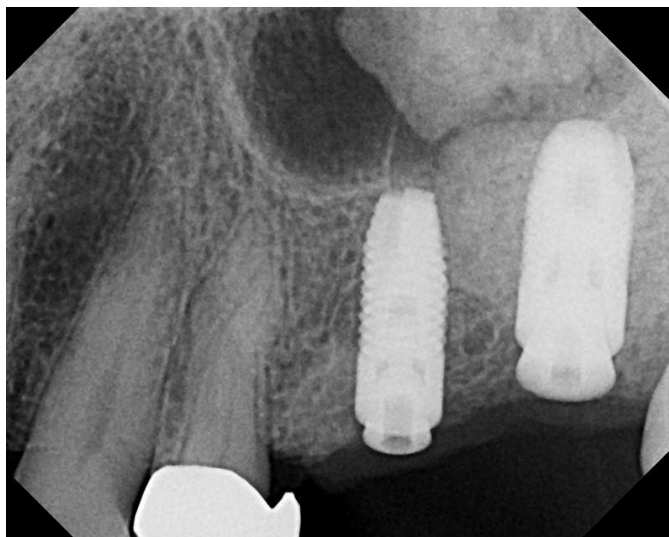Pre op with failing #14. Tooth Extracted and grafted with Socket Graft.



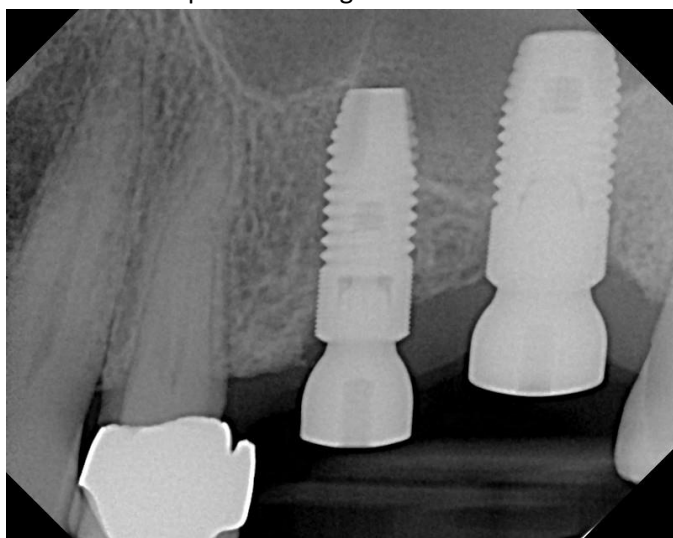
03/01/2011 Sinus Augmentation pre op



03/01/2011 Steiner Sinus Lift complete with trephines for core sample. The sclerotic bone on the crest was a result of a previous allograft.



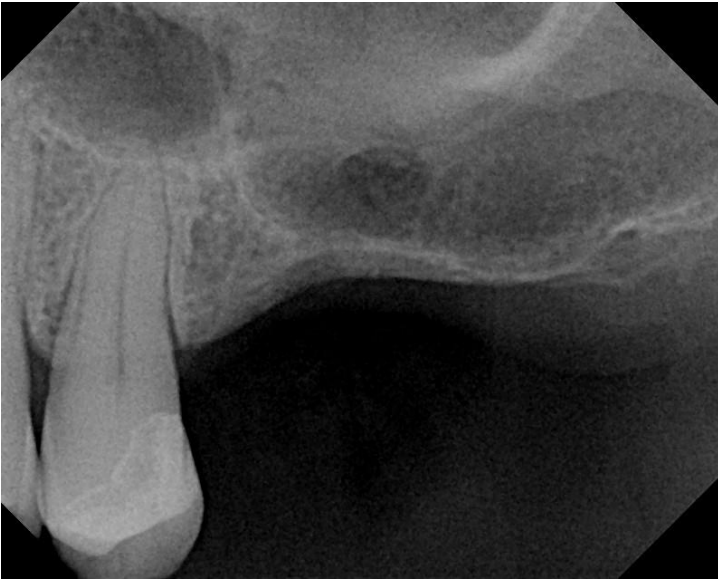03/01/2011 Implants placed.



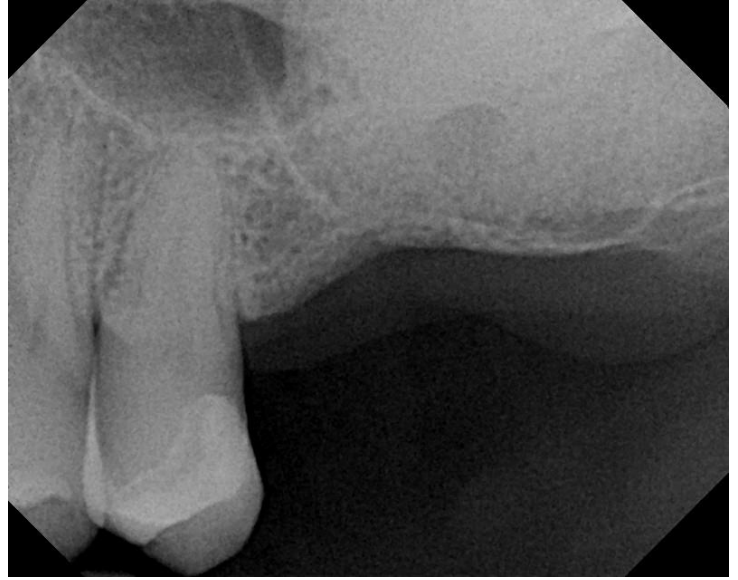11/16/2011 Healing abutments placed.

ID: Pry

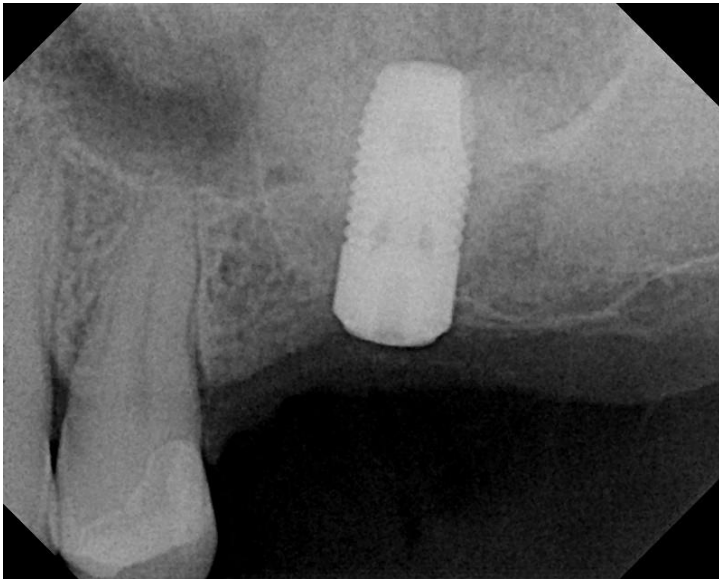
#28



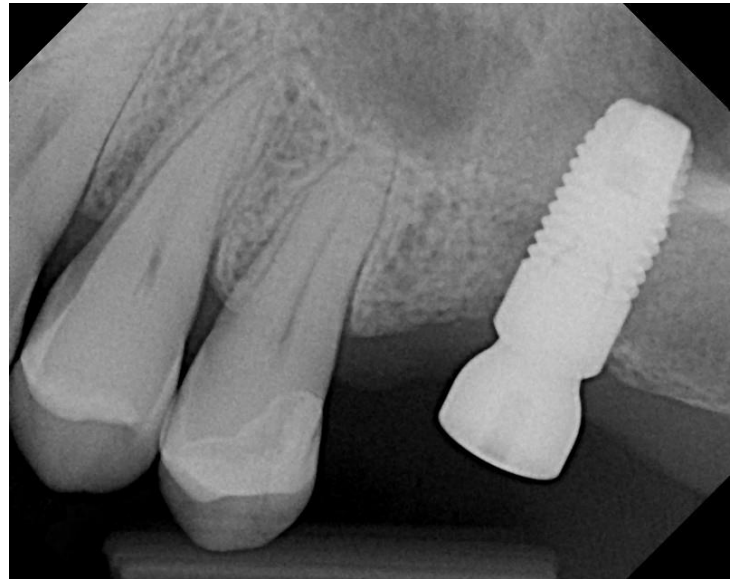
04/13/2011 Steiner Sinus Lift with osteotomy.



04/13/2011 Steiner Sinus Lift complete.



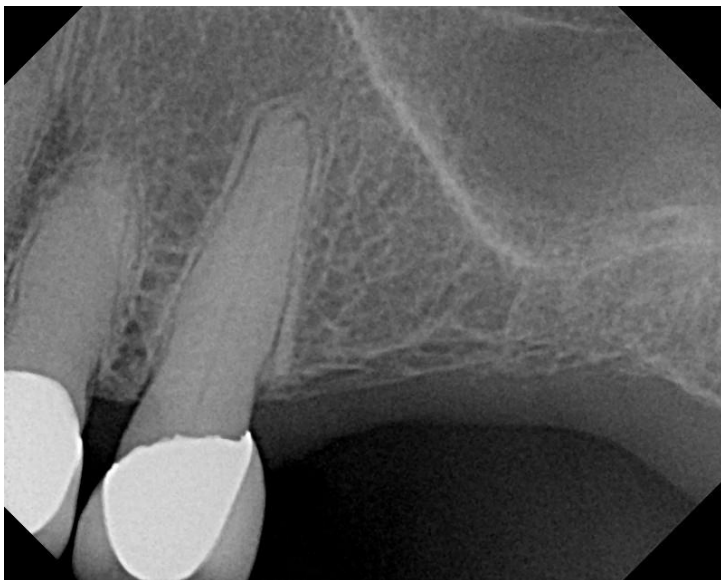04/13/2011 Steiner Sinus Lift complete with implant.



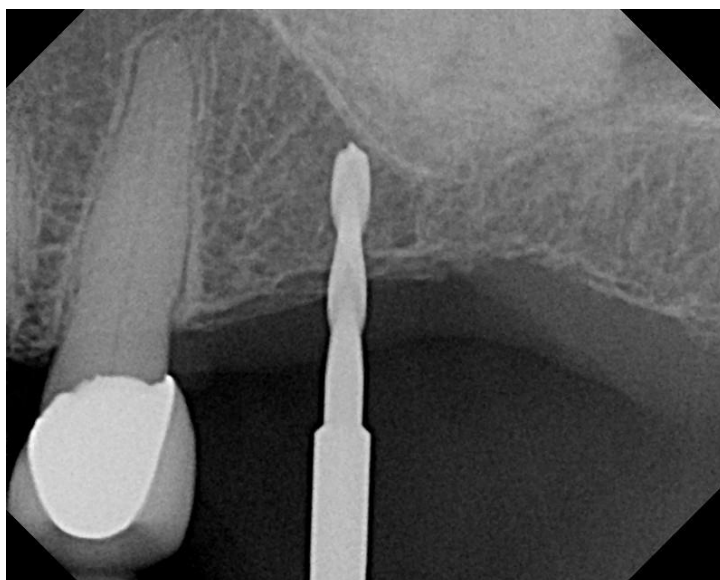
07/20/2011 Healing abutment placed and referred for restoration.

ID: Rud

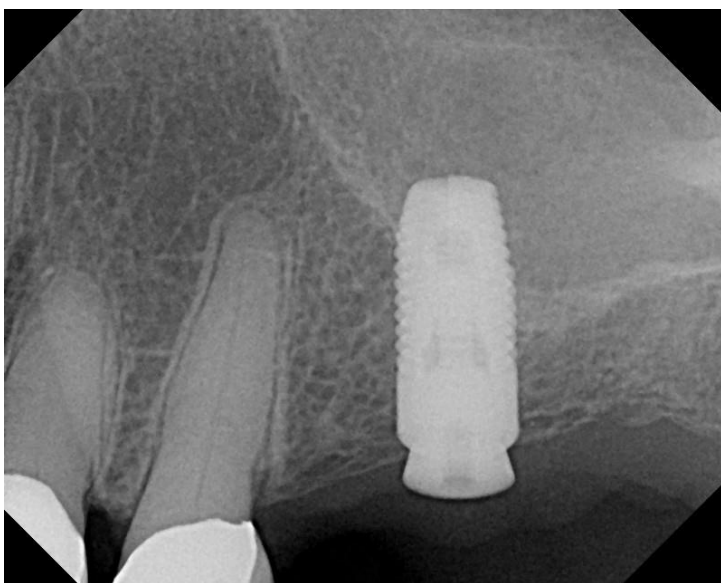
#29



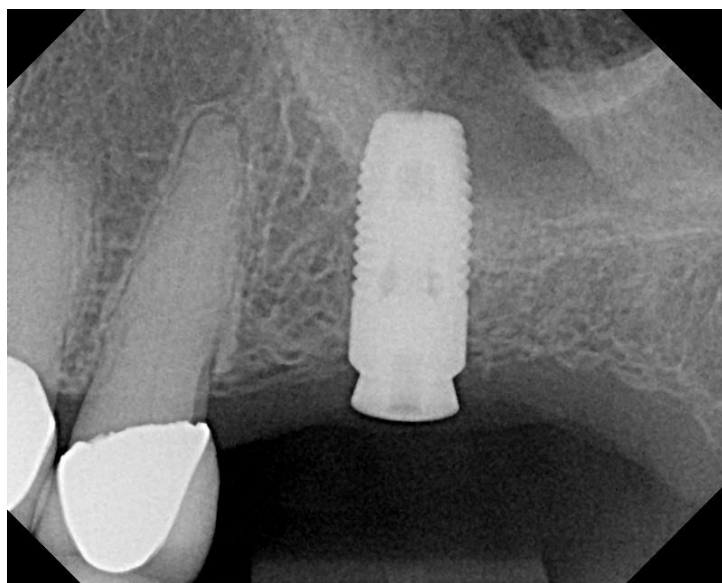
Pre op



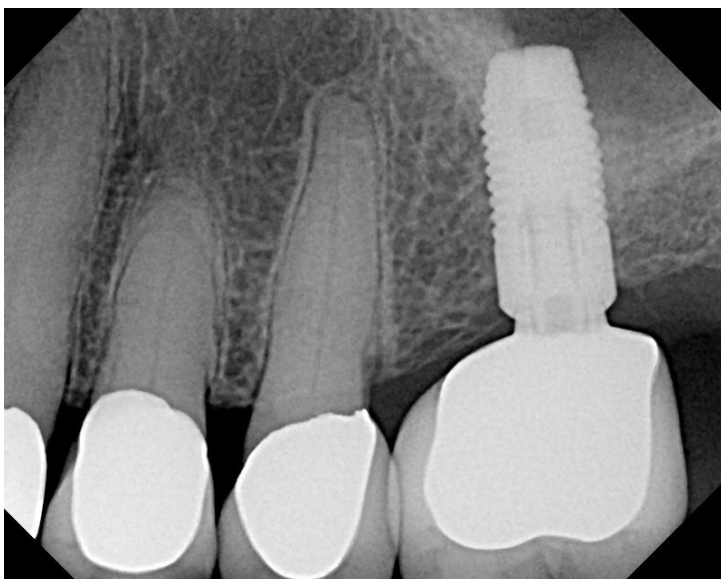04/14/2011 Steiner Sinus Lift complete.



04/14/2011 Implant placed.



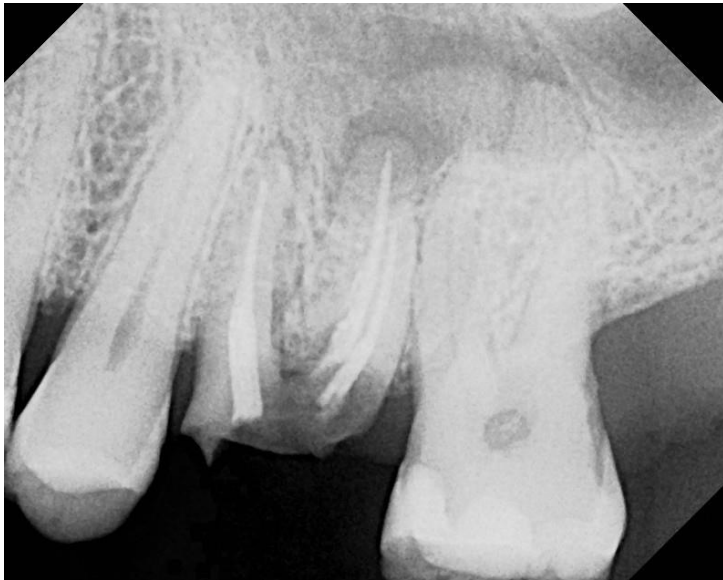07/20/2011 Healing abutment appointment.



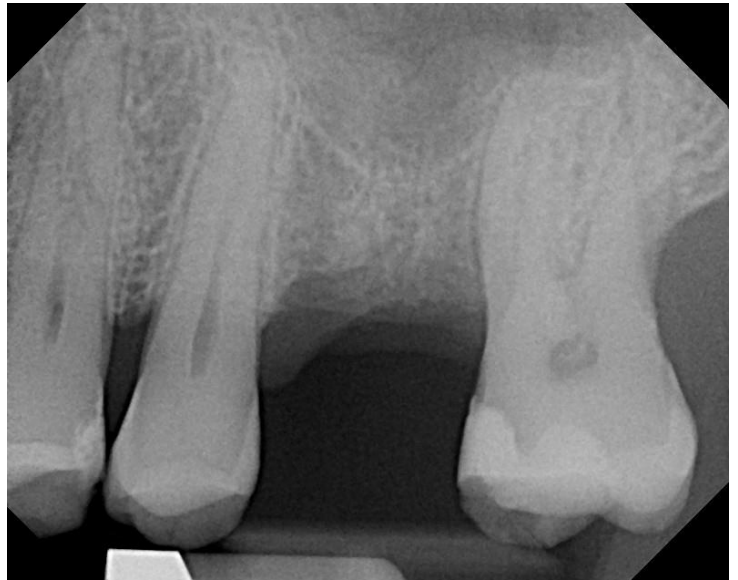05/22/2012 post op

ID: Ker

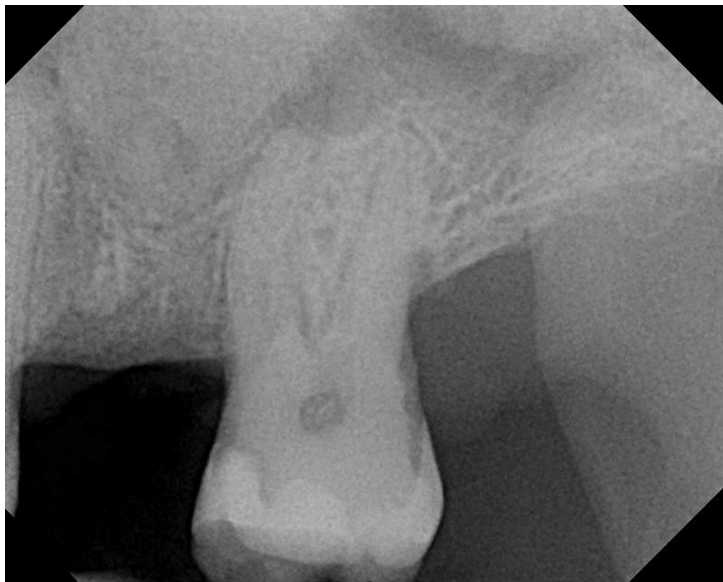#30



04/26/2011 extracted and graft with Socket Graft

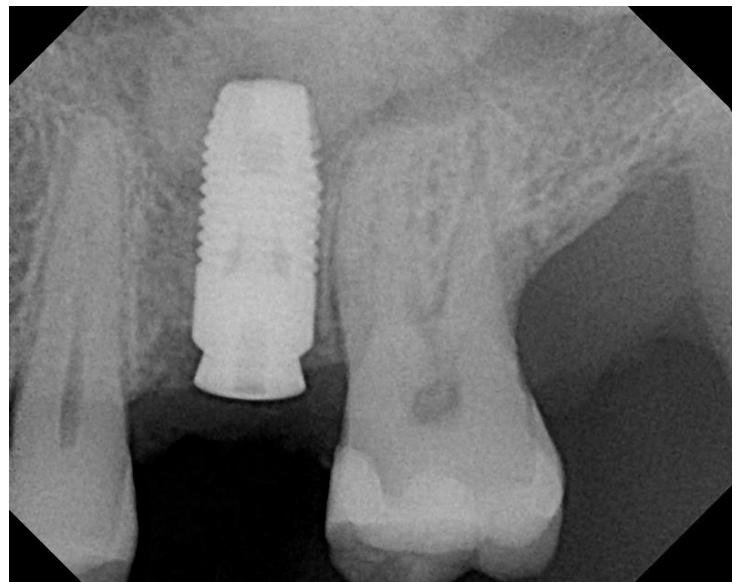


08/03/2011 Pre op sinus lift

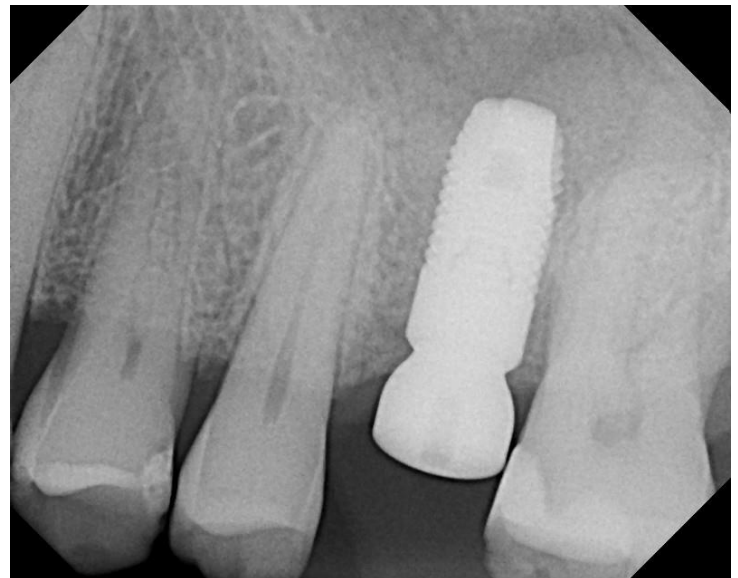


08/03/2011 Steiner Sinus Lift

08/03/2011 Steiner Sinus Lift with implant

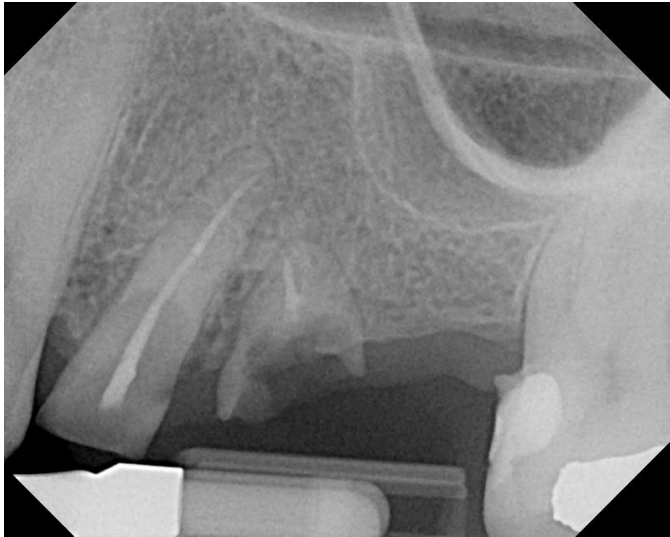

10/12/11 Healing abutment
placed and referred for restoration

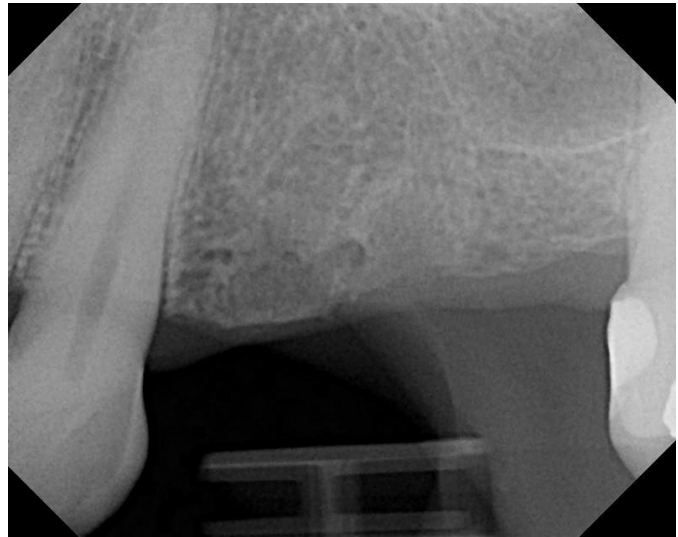


ID: Dumo

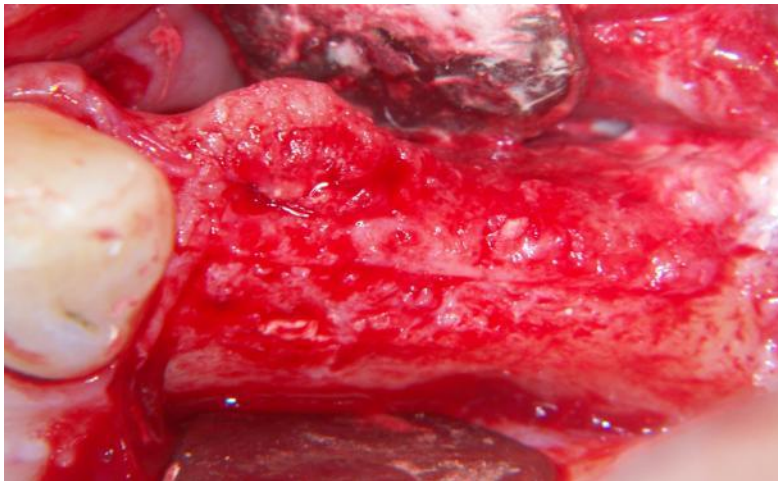
#31



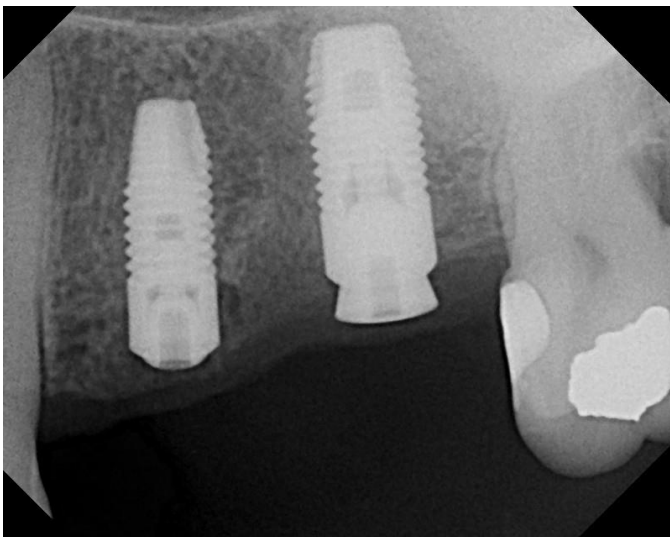
Pre op 08/18/2011



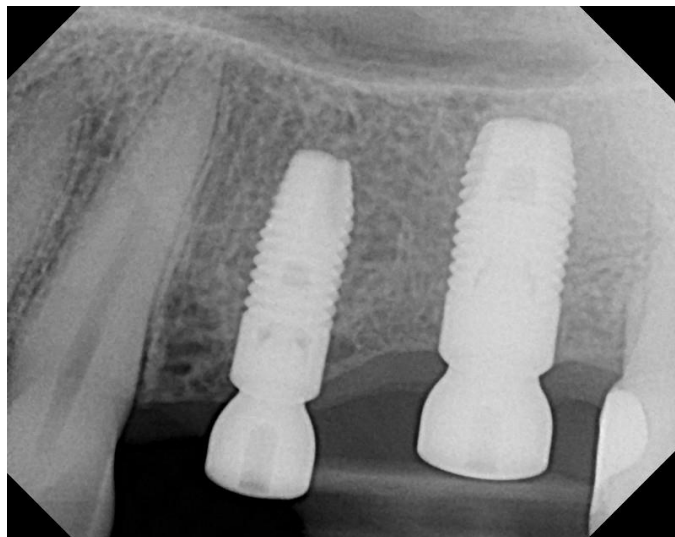
06/08/2011 Teeth extracted and grafted with Socket Graft



Pre op ridge after grafting with Socket Graft 08/18/2011



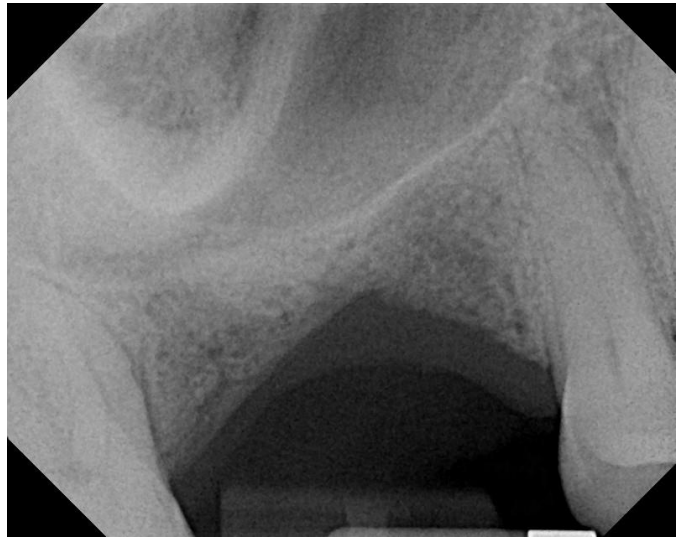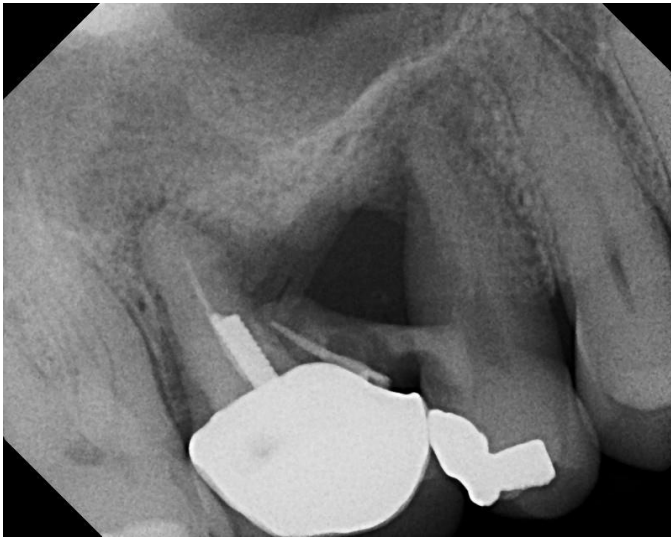08/18/2011 Steiner Sinus Lift and Implant placement



11/17/2011 Healing abutments placed

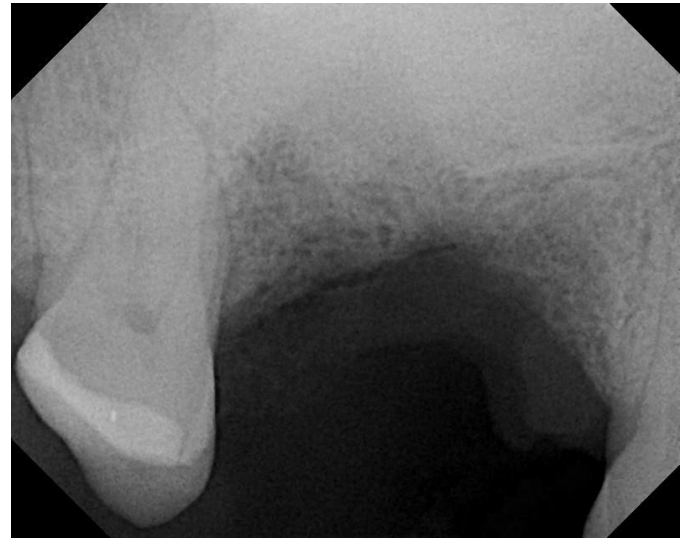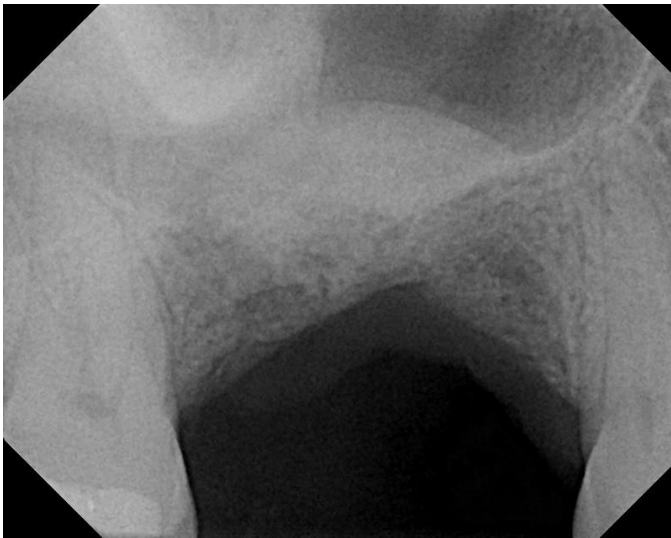ID: Dupl

#32



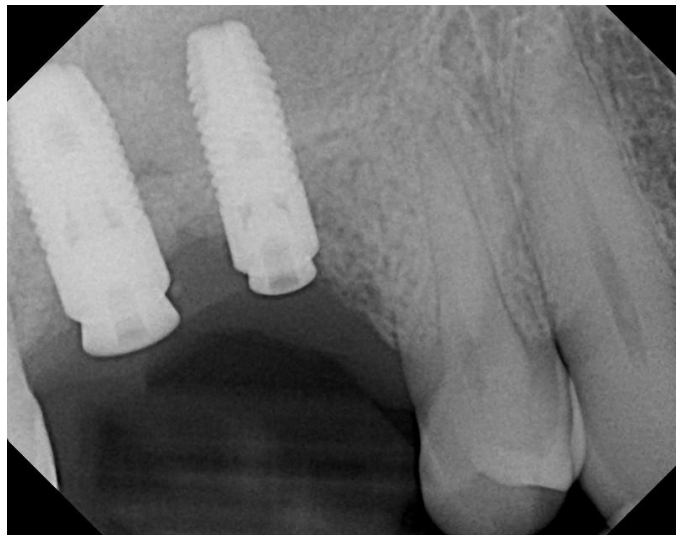
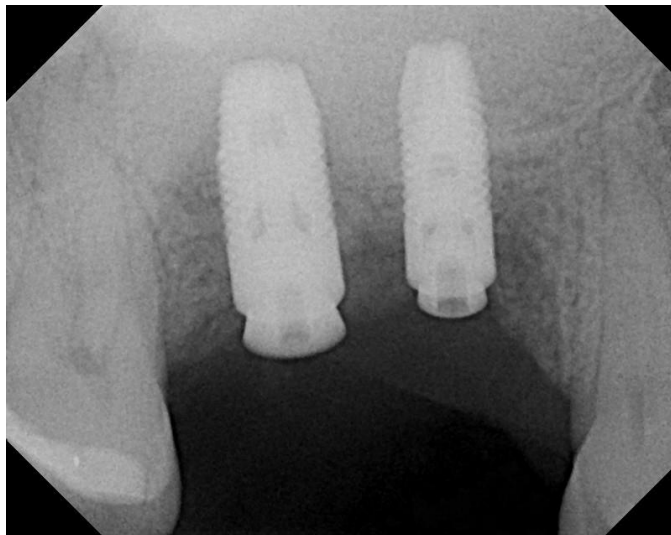06/08/2011 Teeth extracted and grafted with Socket Graft Putty

01/04/2012 Pre op sinus augmentation and implant



01/04/2012 First 2 cc's Sinus Graft™

01/04/2012 Steiner Sinus Lift Complete

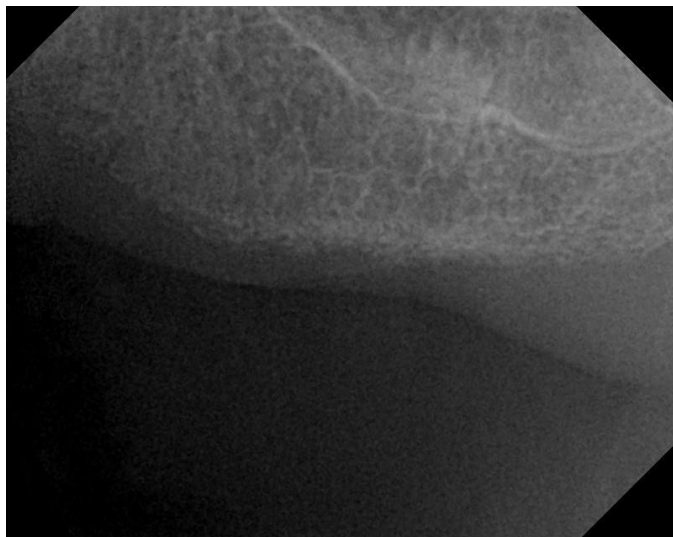
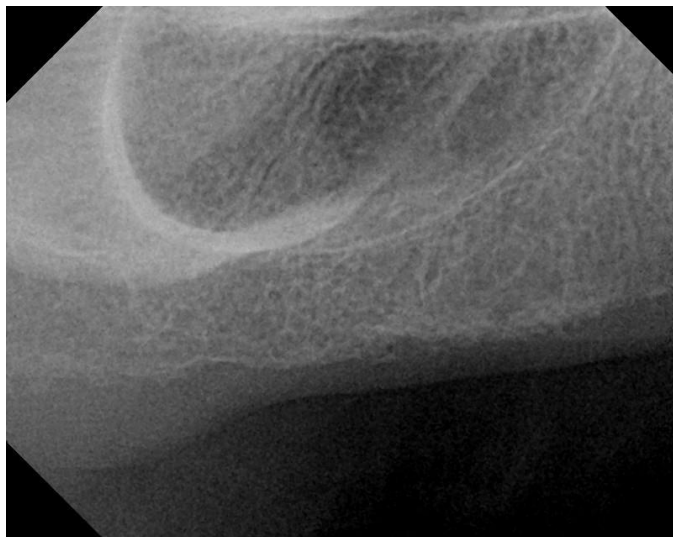

01/04/2012 Implants placed

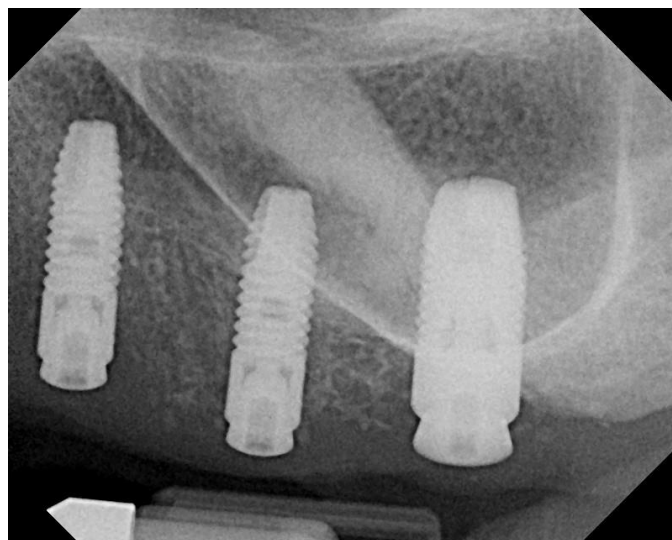
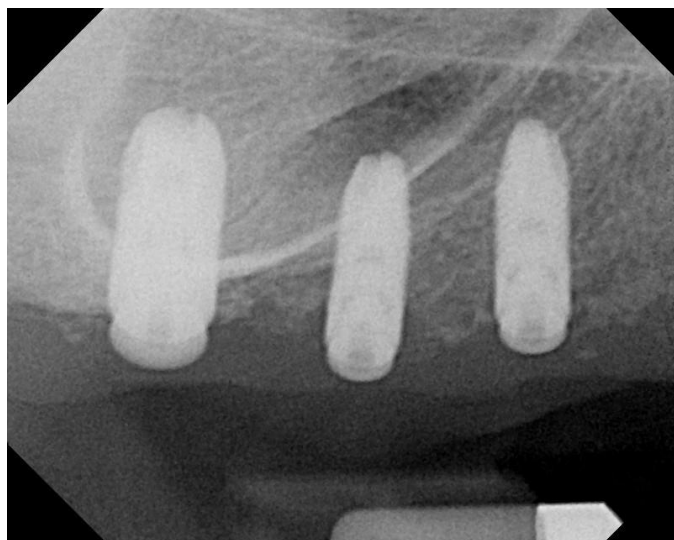
03/28/2012 Healing abutment appointment

ID: Gric

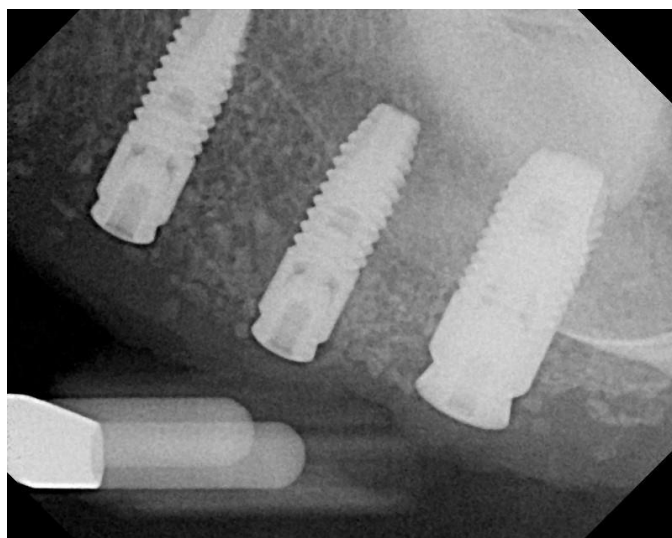
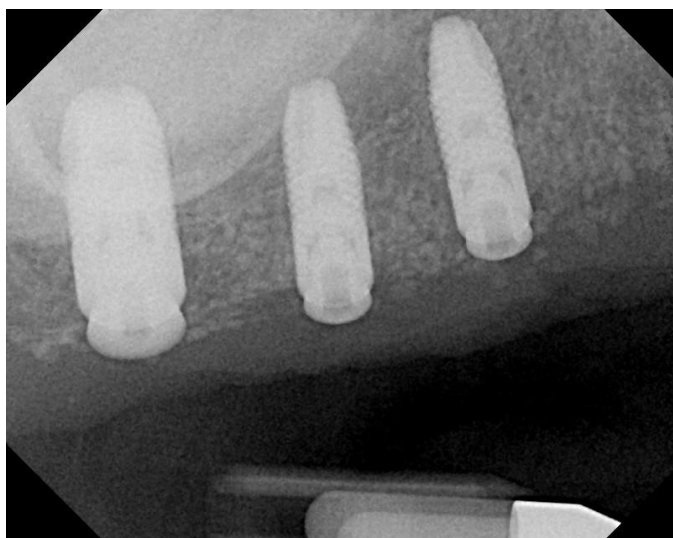#33



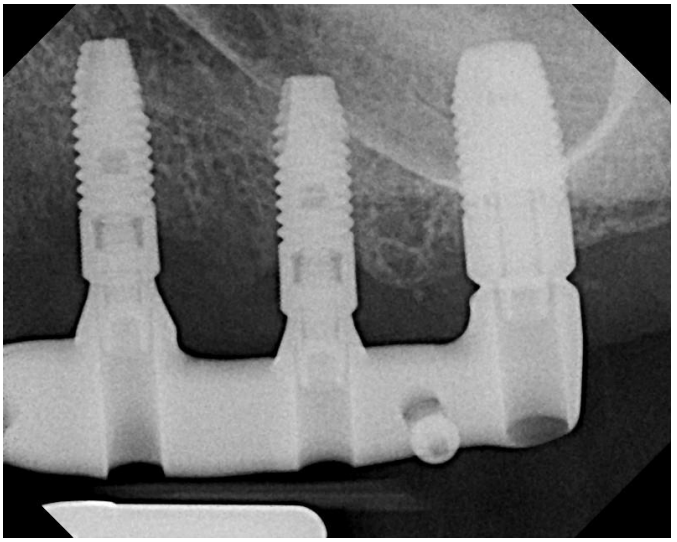
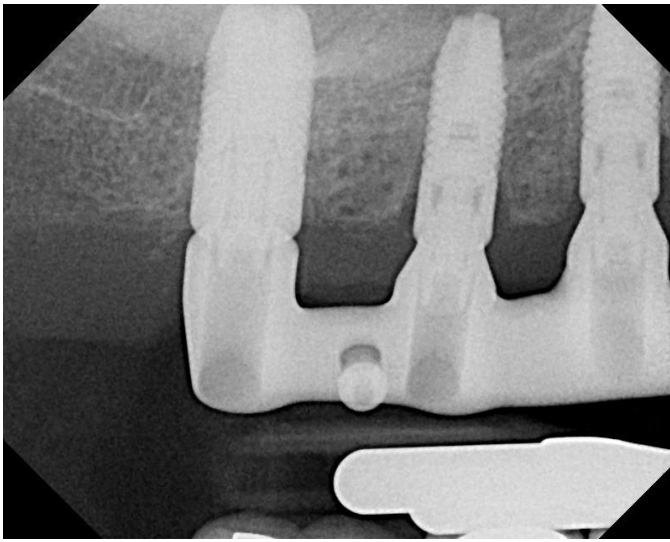
Pre op radiographs



06/21/11 Steiner Sinus Lift complete UR and UL with six implants placed in the maxilla.

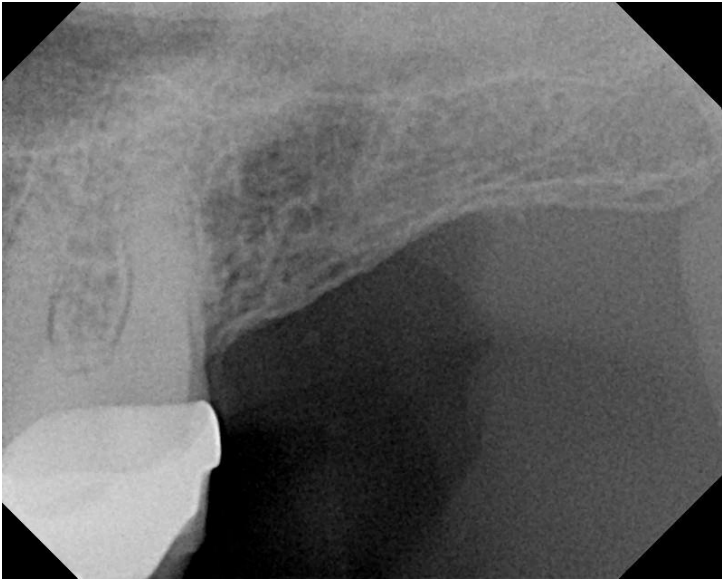

09/28/2011 Healing abutment appointment.

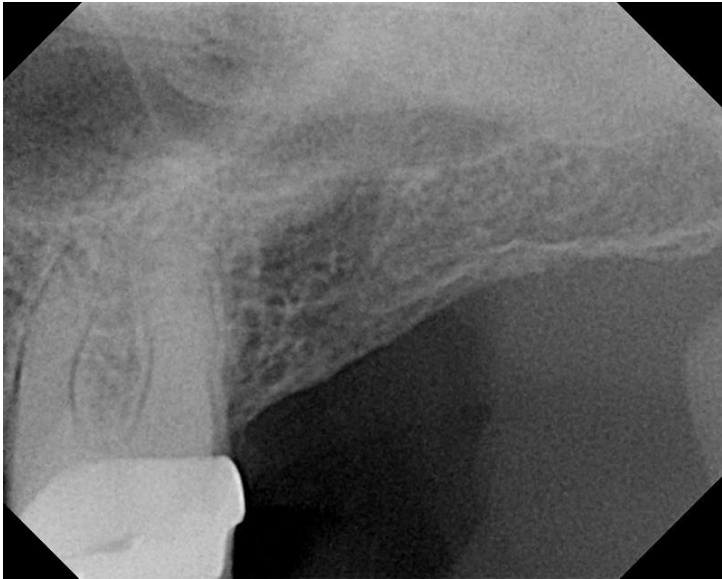


02/15/2012 Restored with a milled bar.

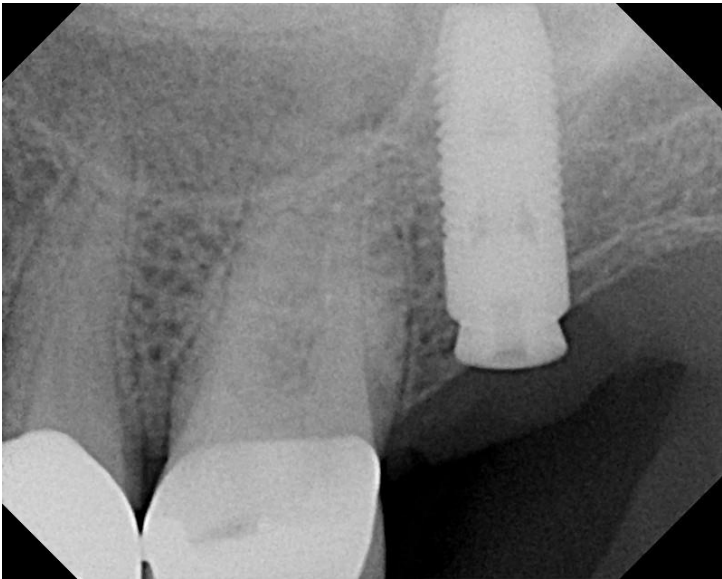ID: Ful #34



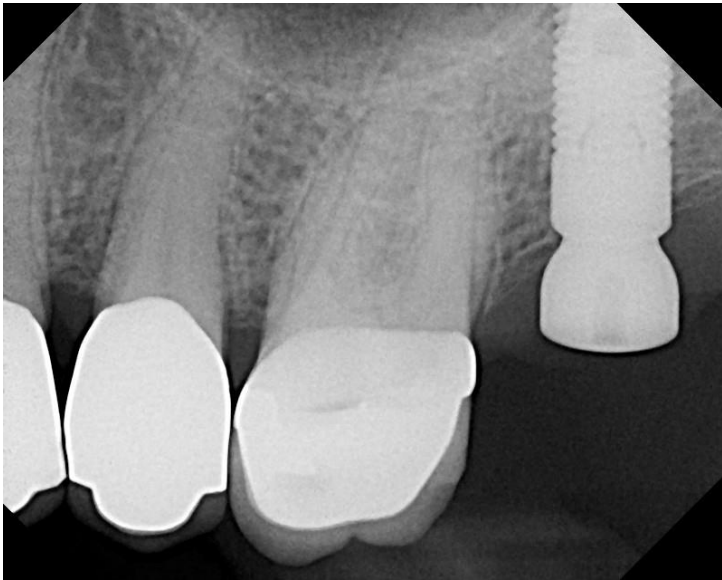Pre op



08/04/2011 Steiner Sinus Lift complete.



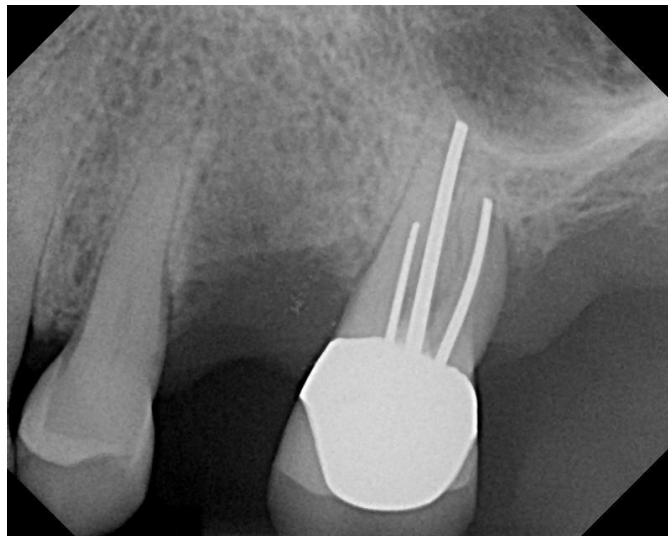
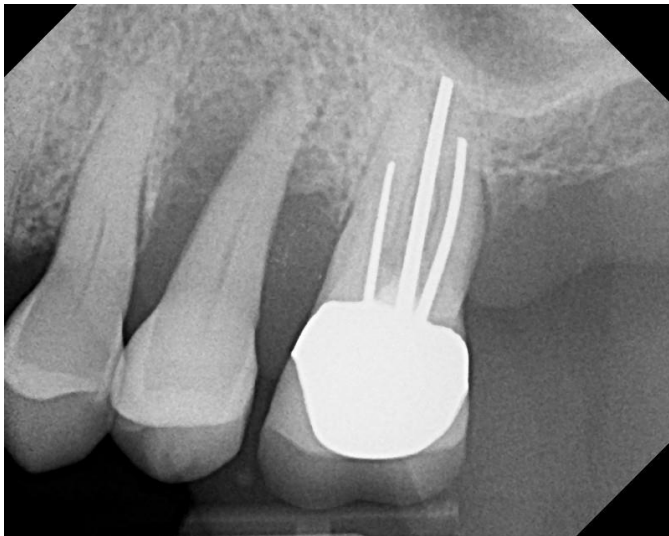
08/04/2011 Implant placed



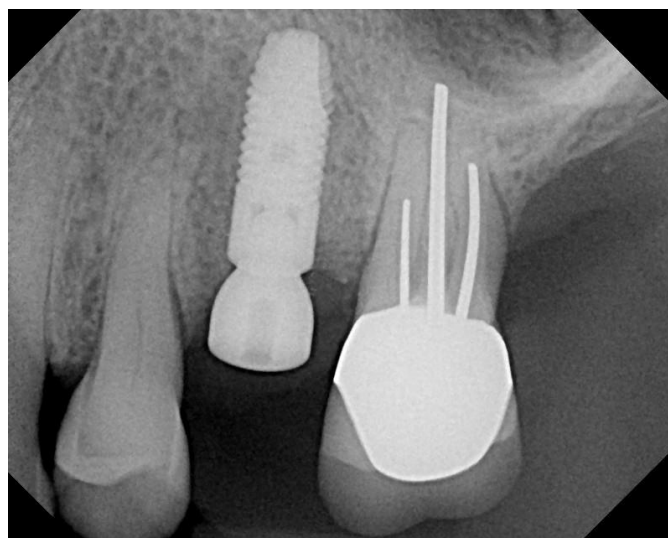
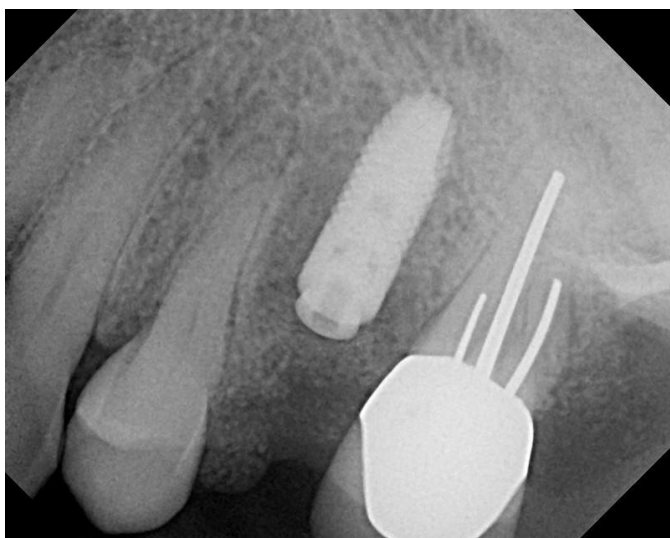11/08/2011 Healing abutment placed patient referred for restoration.

ID: Blo

#35

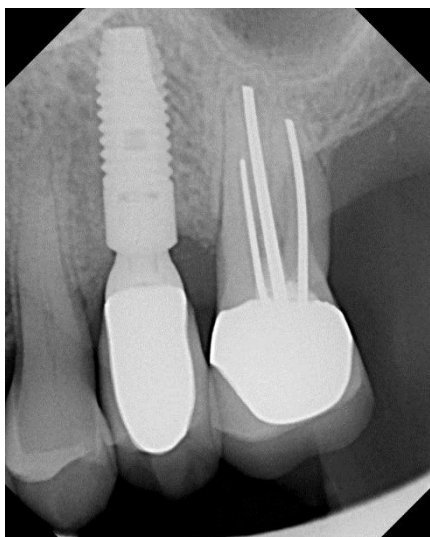


12/08/2011 #13 extracted and grafted with Socket Graft Putty. 03/14/2012 Sinus Lift pre op. Floor of sinus located approximately 4 mm apical to the palatal molar root tip.

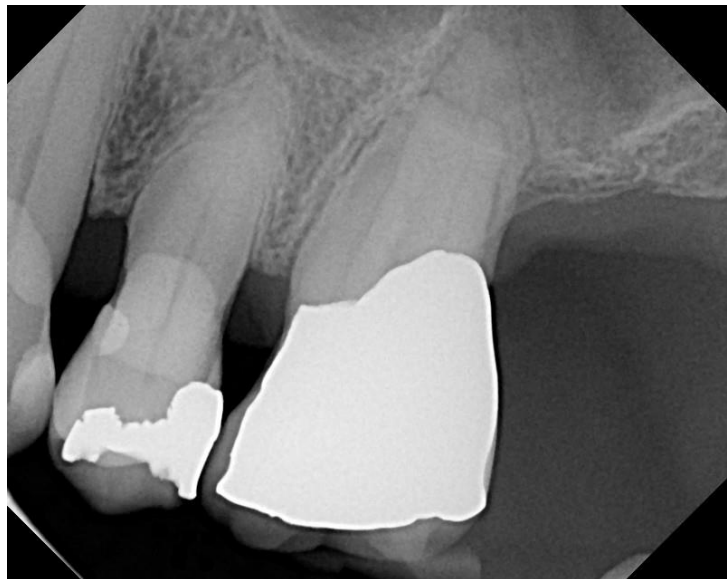

03/14/2012 Steiner Sinus Lift and implant placement

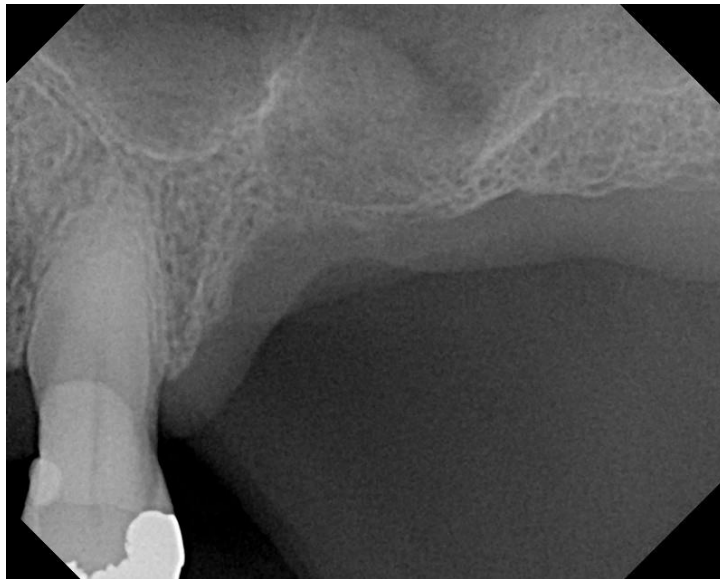06/20/2010 Healing abutment



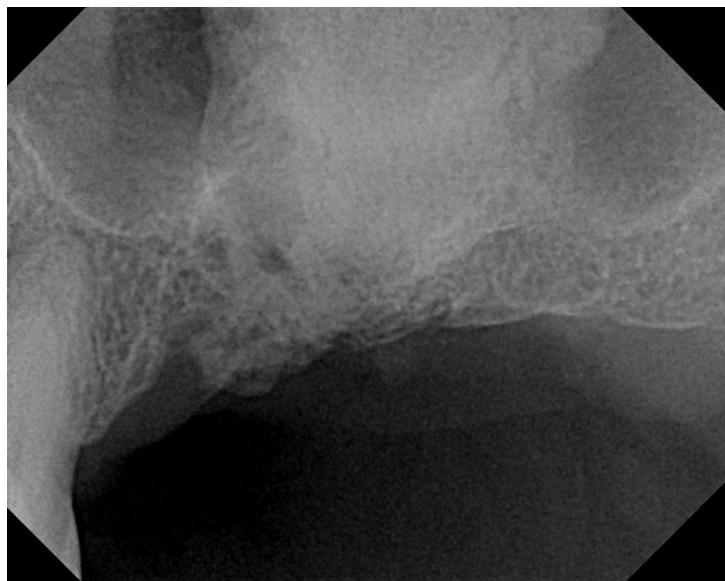
Restored- note the bone regeneration on the mesial of #14 as compared to the pre op radiograph.



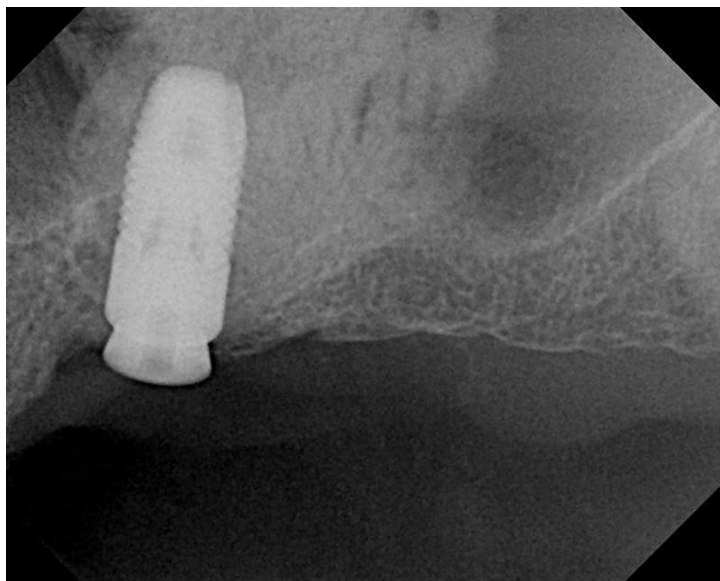
12/20/2011 Pre op



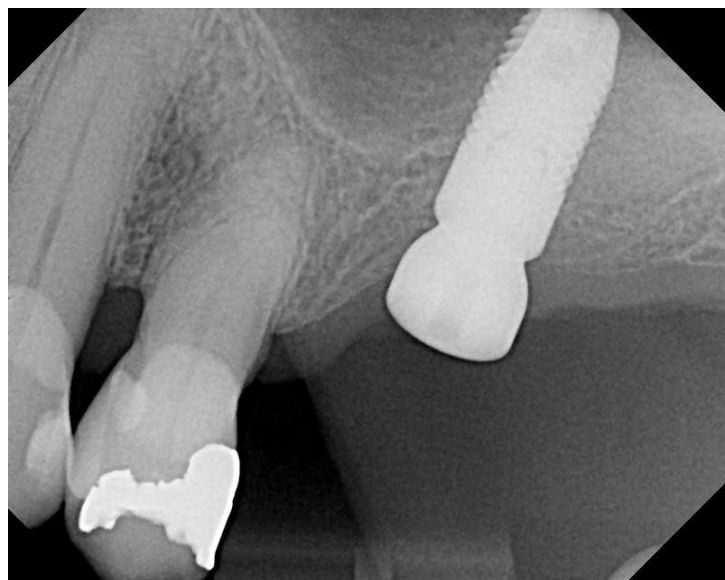
03/13/12 Pre op



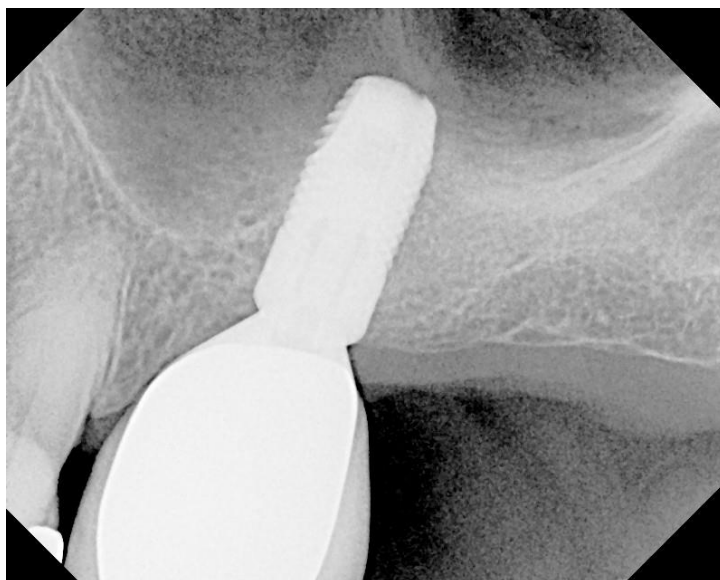
03/13/12 Steiner Sinus Lift.



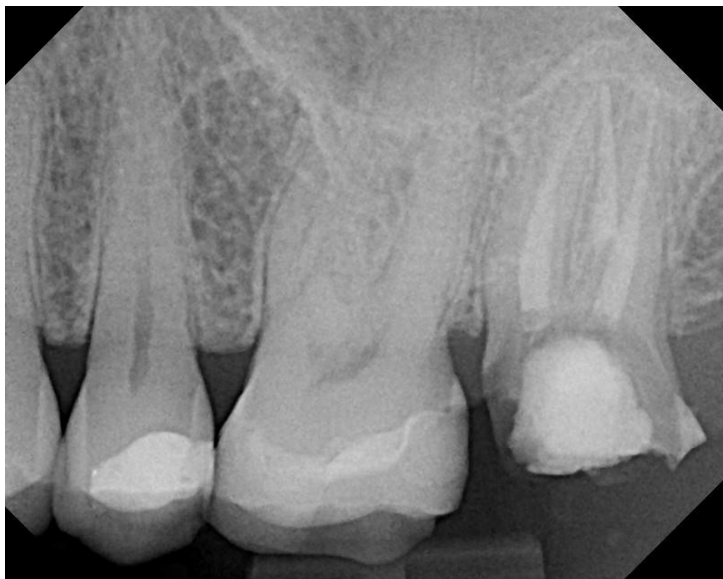03/13/12 Steiner Sinus Lift with implant.



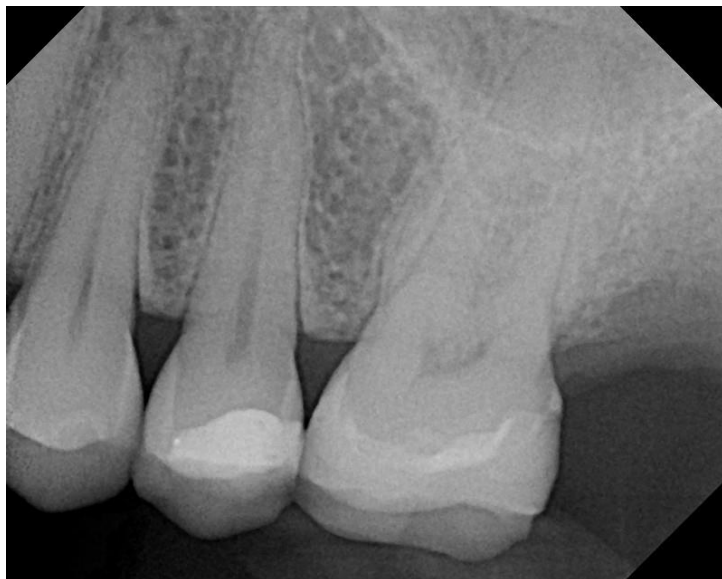06/19/2012 Healing abutment placed.



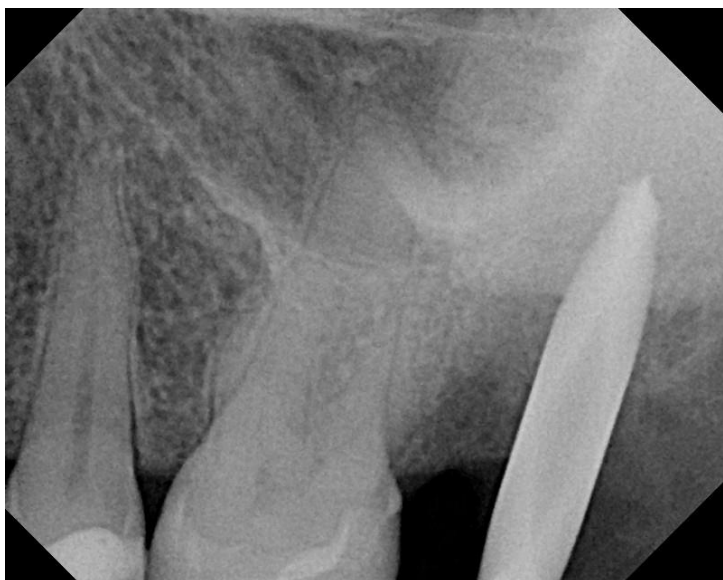Restored



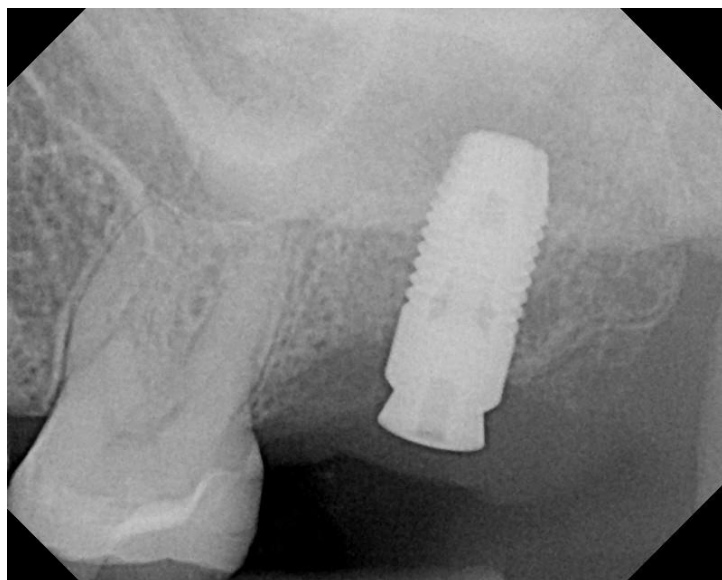
10/25/2011 #15 extracted and grafted with Socket Graft.



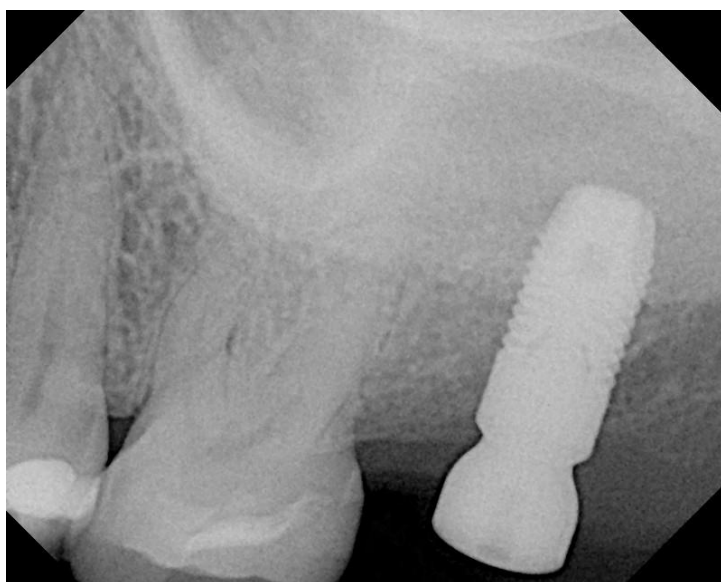
12/06/2011 Pre op.



12/06/2011 Steinier Sinus Lift complete.



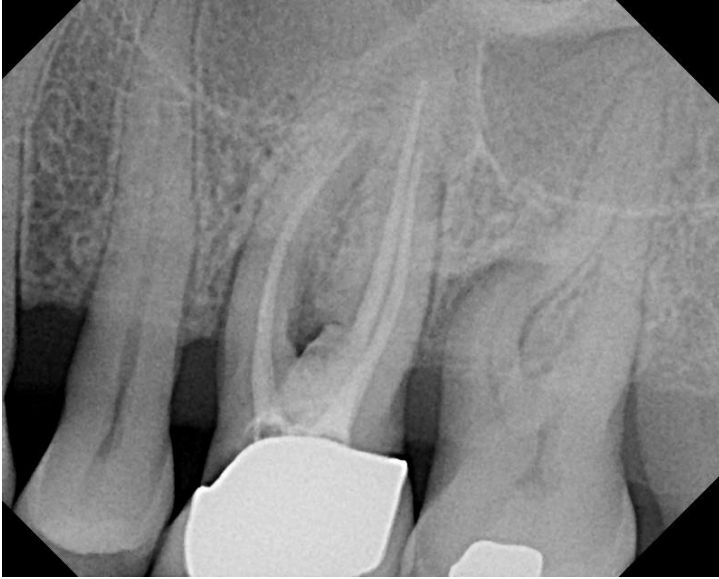12/06/2011 Steinier Sinus Lift complete with implant.



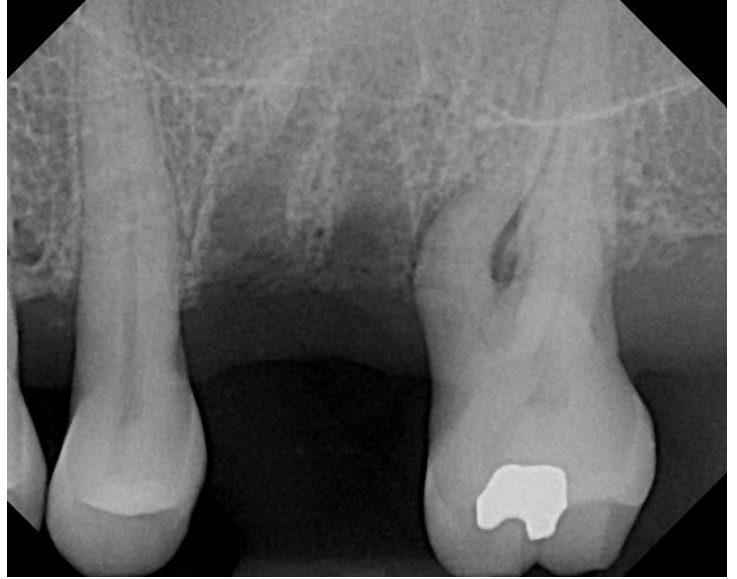12/06/2011 Healing abutment placed and referred for restoration.

ID: Sha

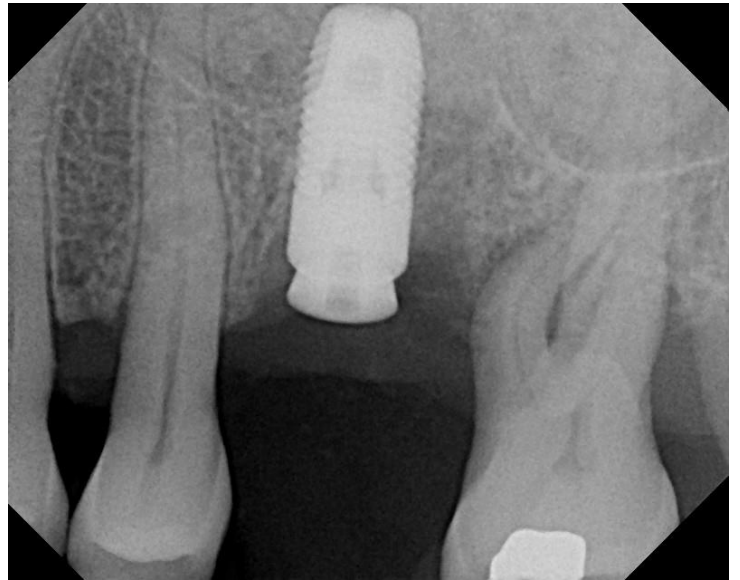
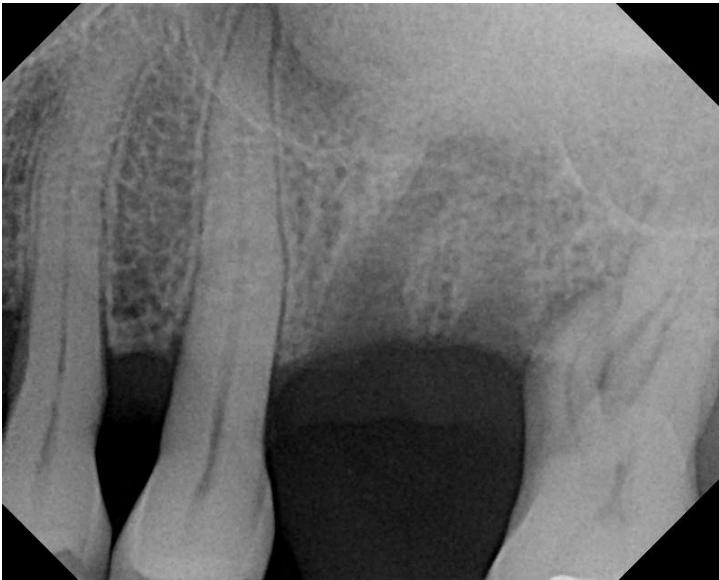#38

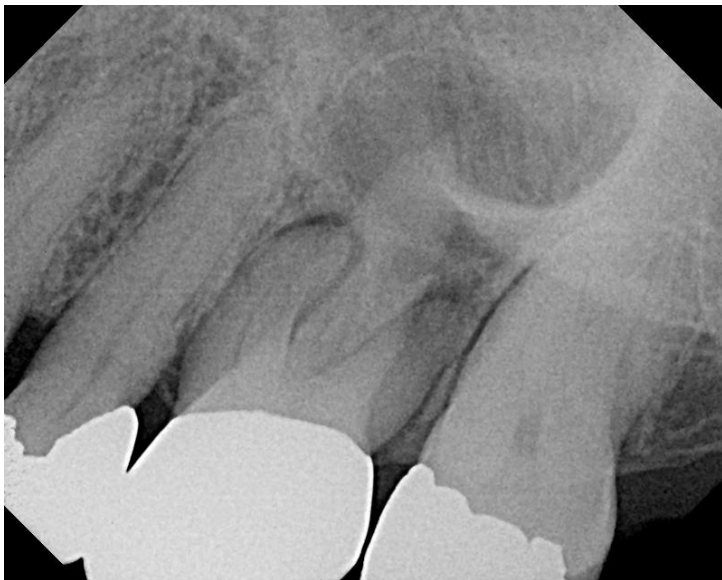

03/29/2012#14 extracted and grafted with Socket Graft

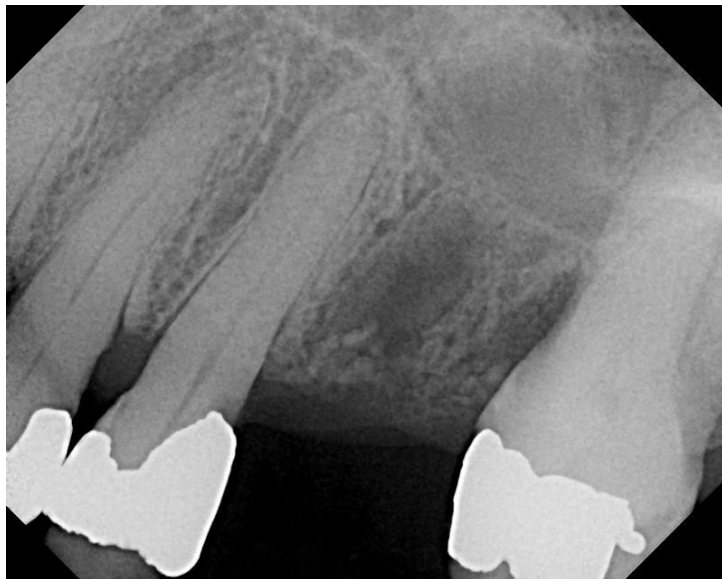

05/24/2012 Sinus lift pre op

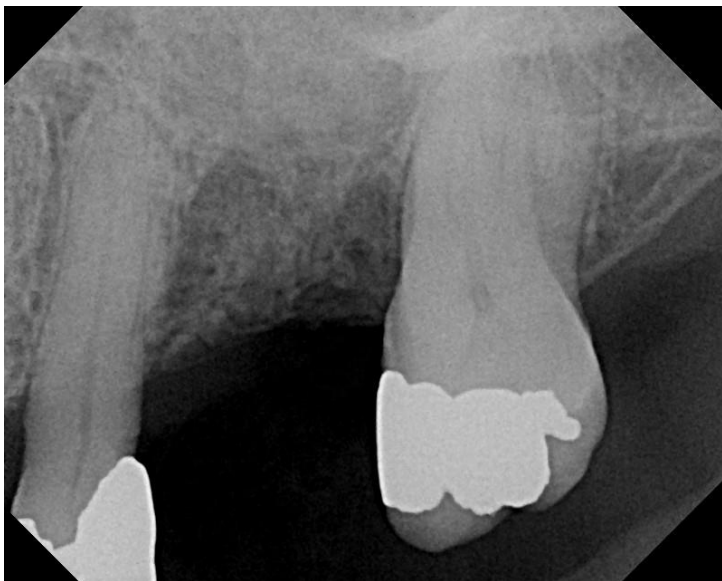



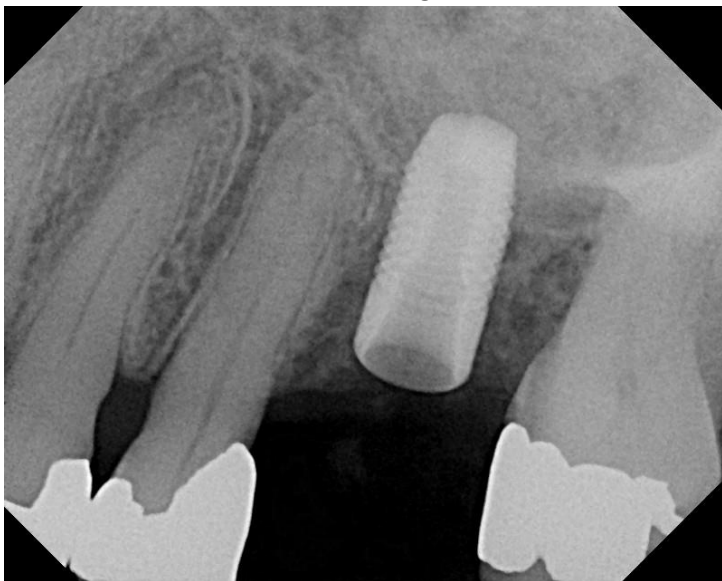05/09/2012 Pre op



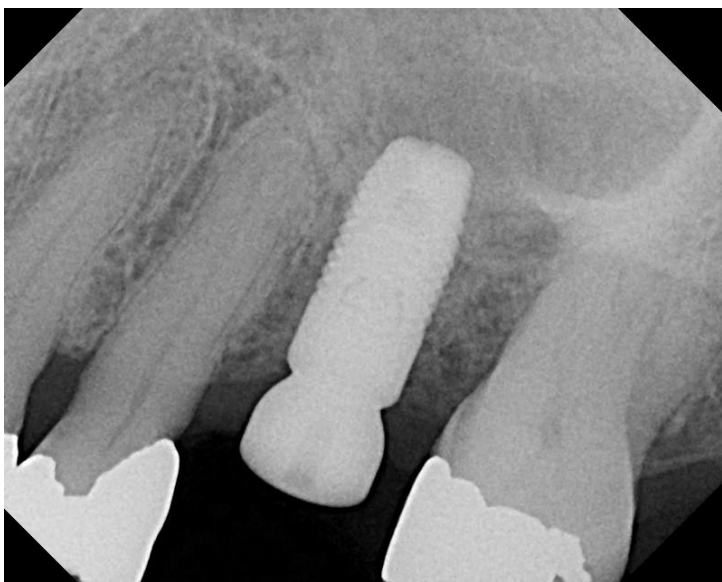07/05/2012 #14 extracted and grafted with Socket Graft and OsseoConduct BTCP standard granules.



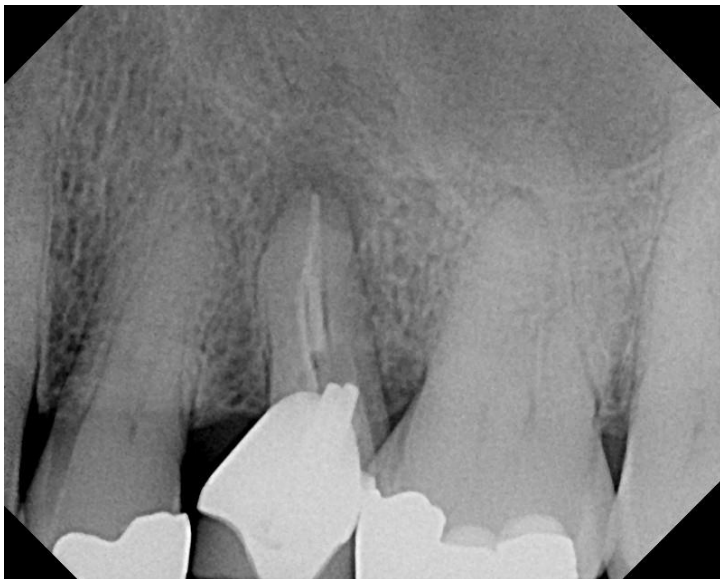05/09/2012 Steiner Sinus Lift complete



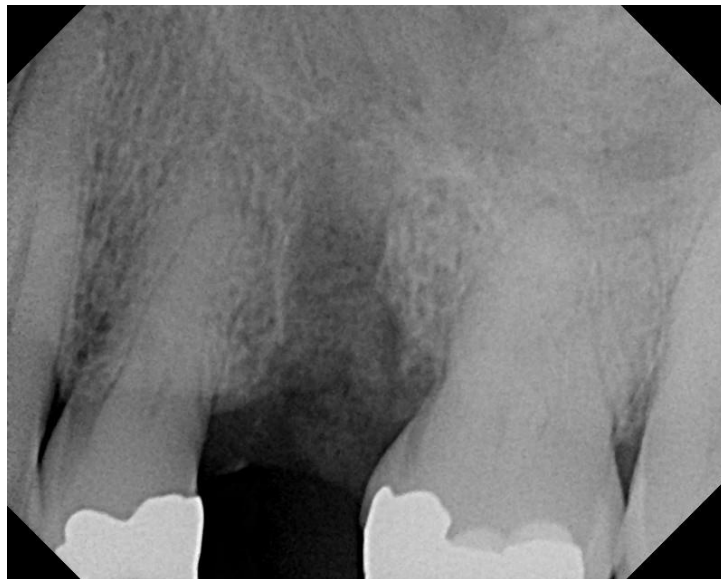05/09/2012 Steiner Sinus Lift complete with implant.



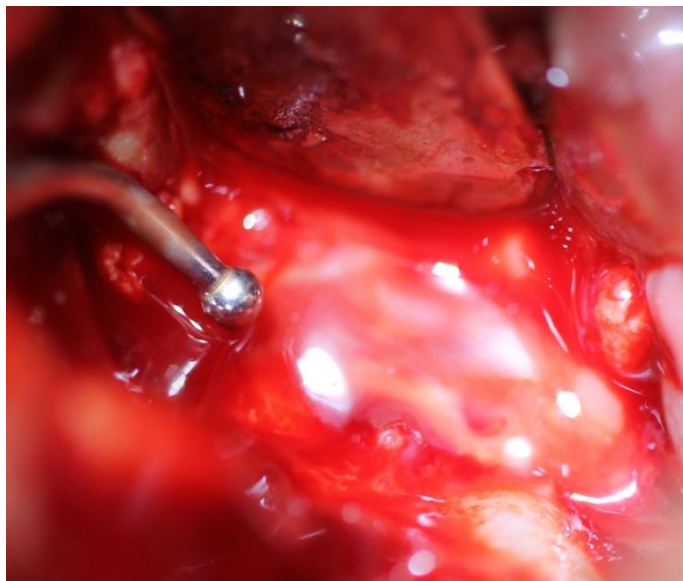
07/17/2012 Healing abutment placed and referred for restoration.



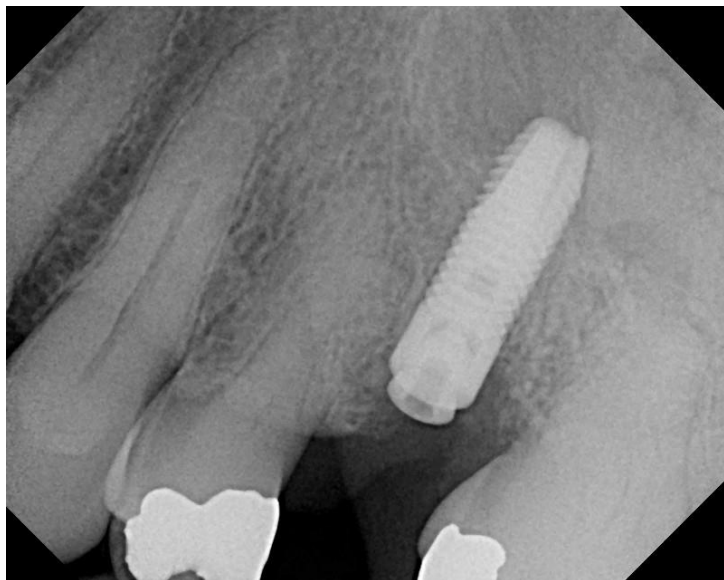Pre Op with infection in sinus



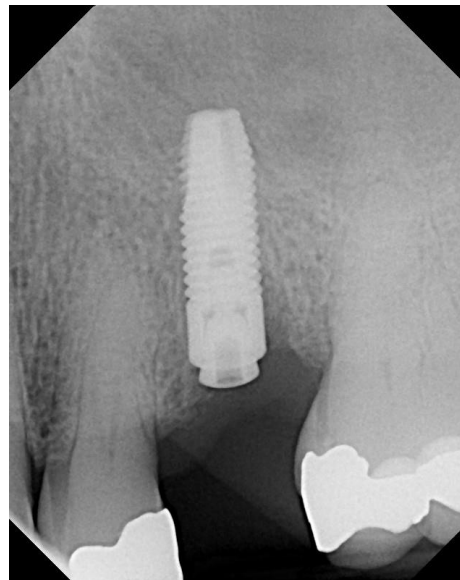
07/18/2012 #13 extracted with Steiner Sinus Lift & socket was grafted with Socket Graft Putty followed by implant placement on the same day.



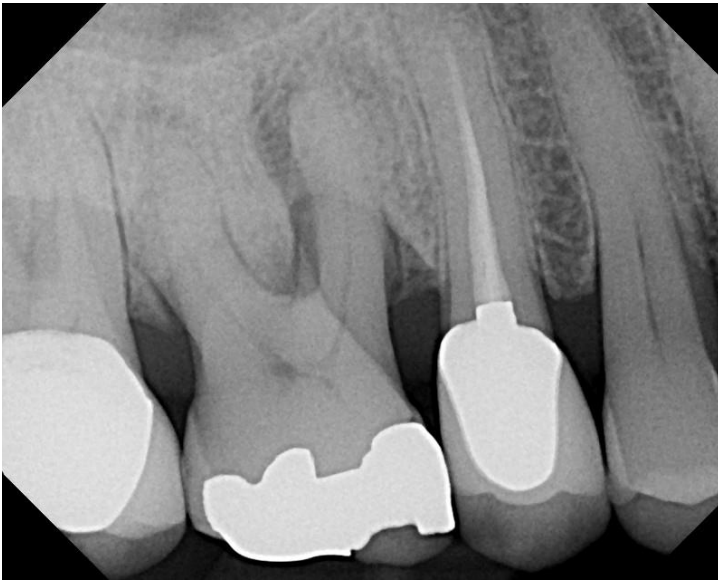The patient presented with a history of sinus pathology and significant congestion prior to the extraction of #13 and sinus augmentation. When dissection of the sinus membrane was started and after the osteotomy was performed, a white milky fluid flowed out of the sinus for the diagnosis of a mucus retention cyst. The fluid was evacuated, the dissection of the sinus membrane was completed and the sinus was grafted with Sinus Graft. The patient's sinus symptoms were resolved.



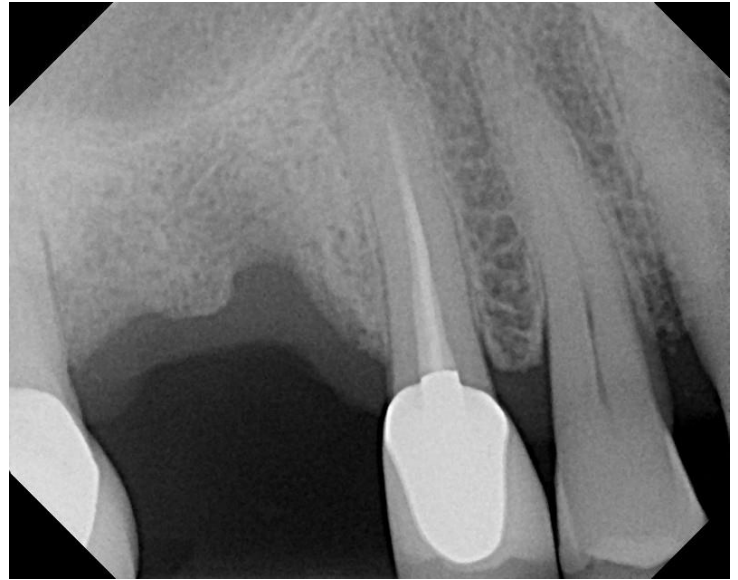
07/18/2012 Implant placement



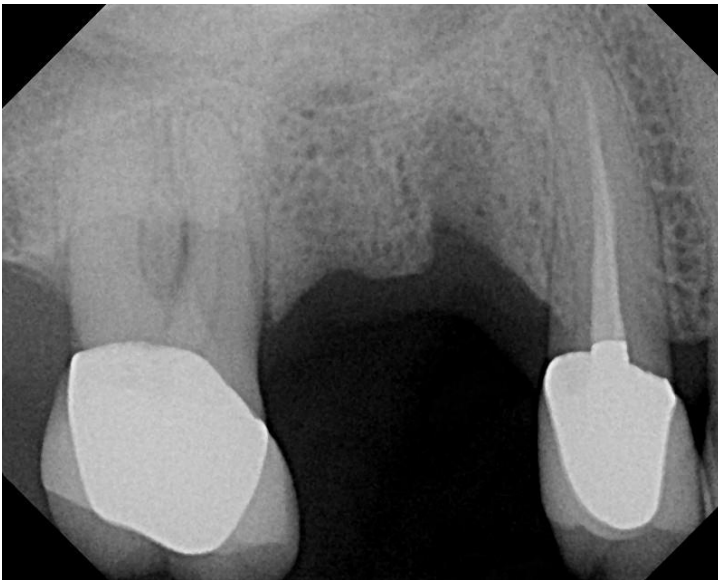10/02/2012 Healing abutment appointment and referred for restoration.



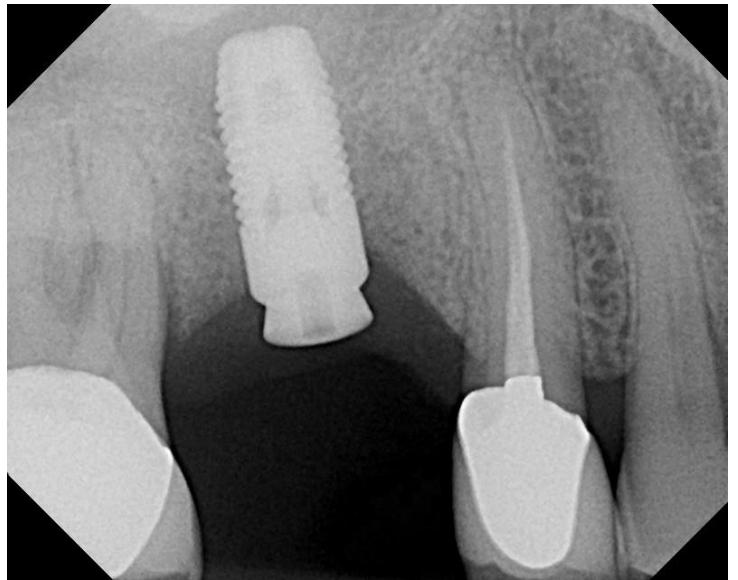
05/23/2012 #3 extracted and grafted with Socket Graft.



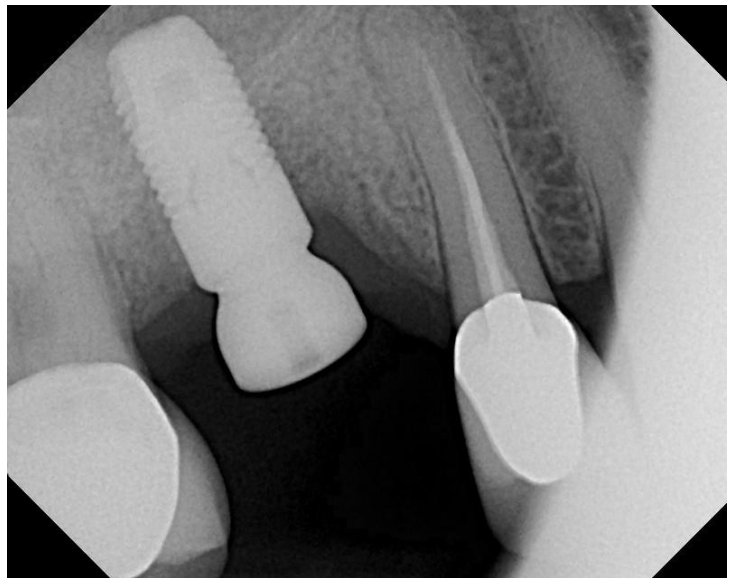
08/15/2012 Pre op for Sinus Lift.



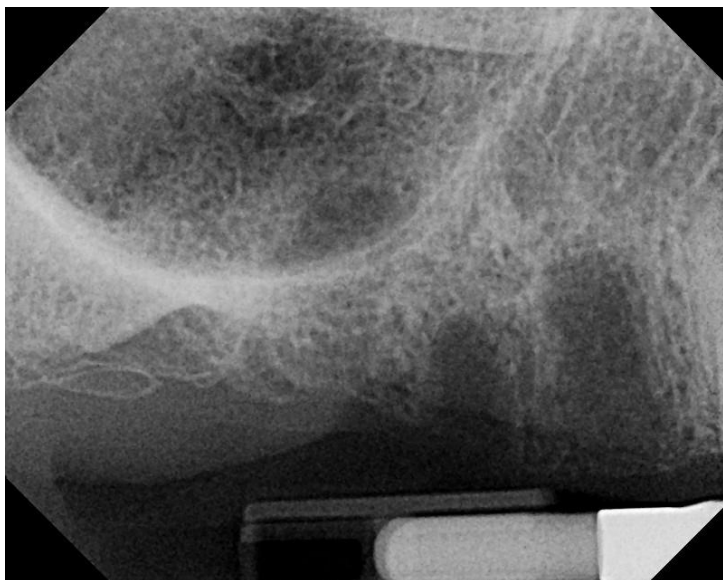08/15/2012 Steiner Sinus Lift complete.



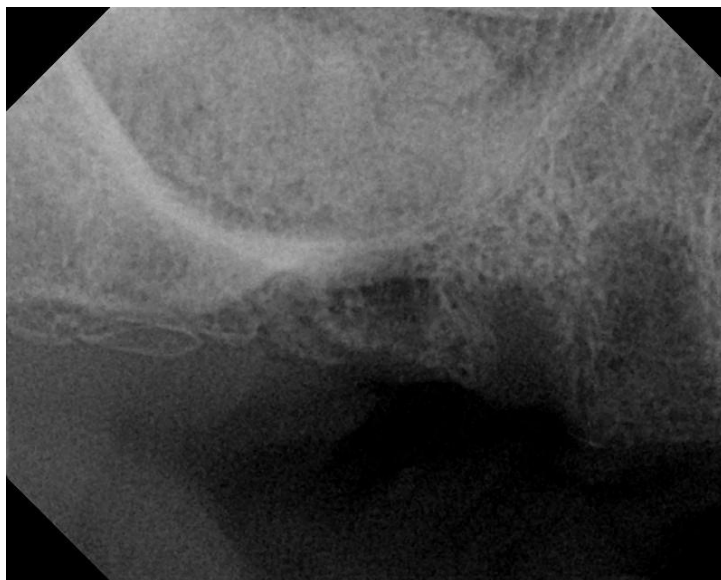08/15/2012 Steiner Sinus Lift complete with implant.



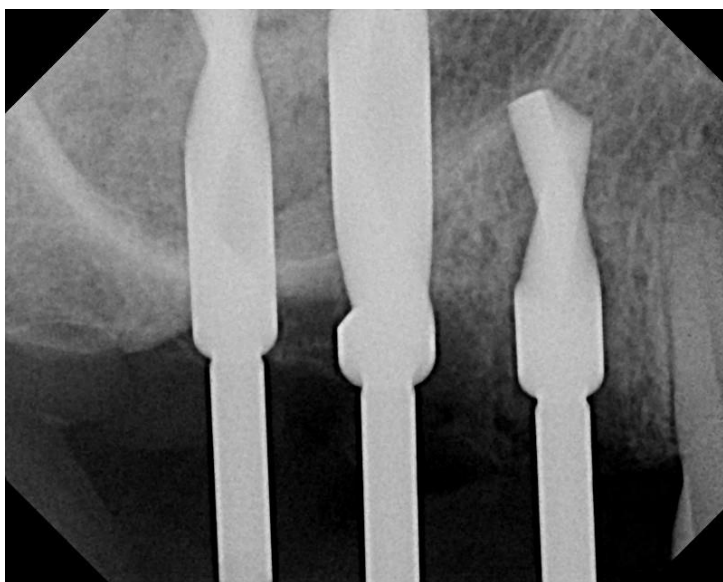
10/30/2012 Healing abutment placed and referred for restoration.



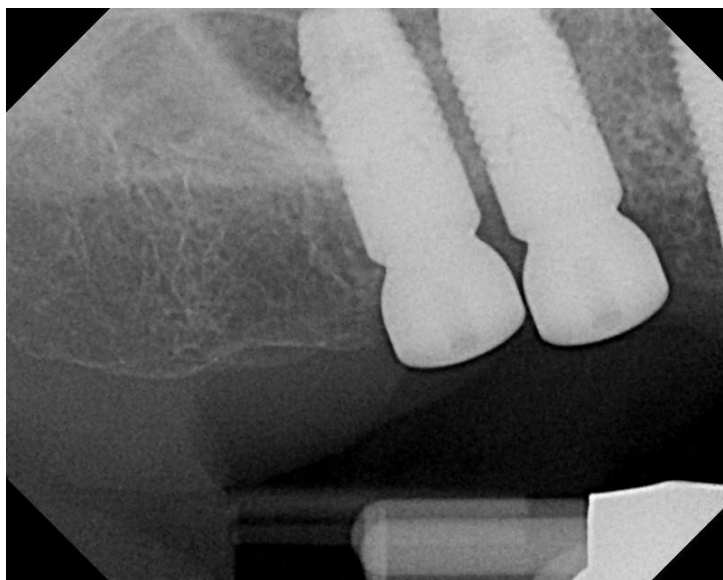
Pre op



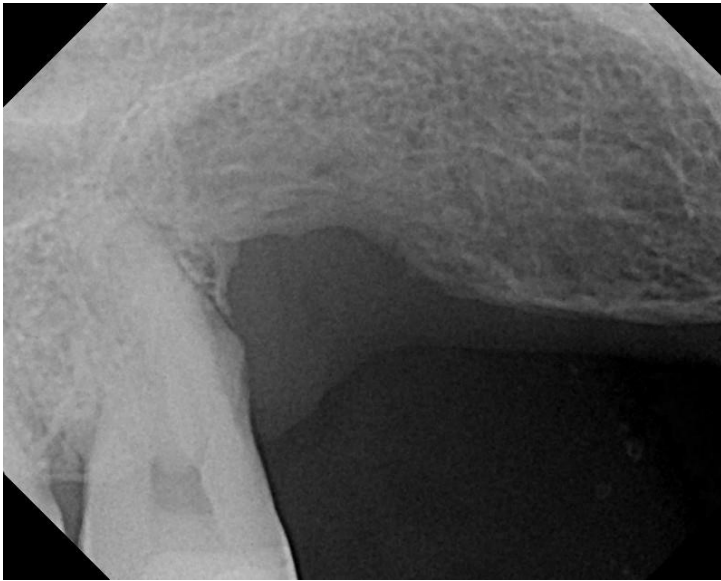
09/12/2012 Steiner Sinus Lift complete



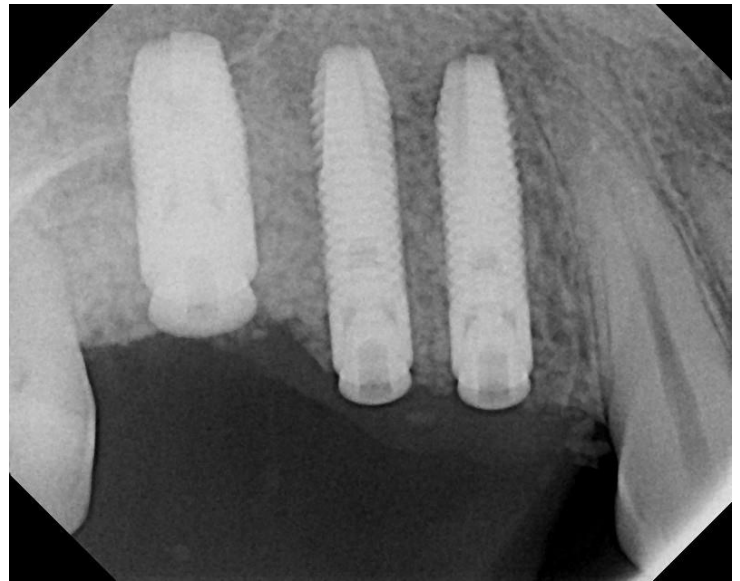09/12/2012 Osteotomies prepared



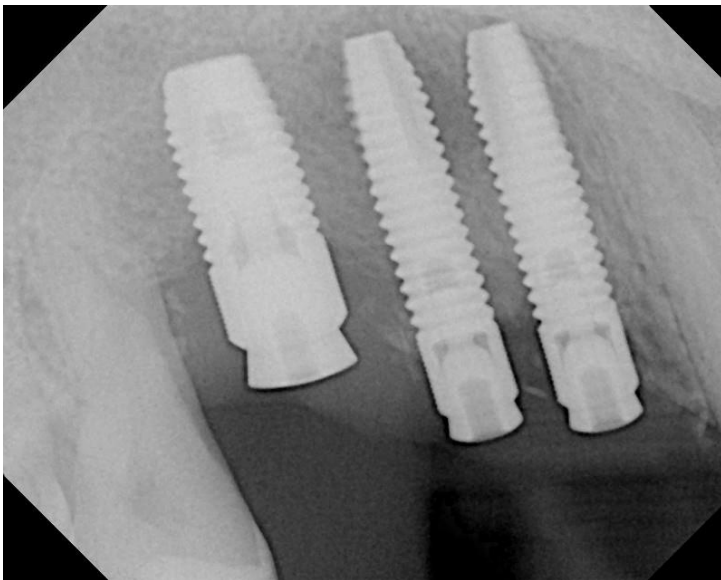
12/18/2012 Healing abutment placed and referred for restoration. As this radiograph shows, the mesial molar implant had drifted distally from the original osteotomy. The reason for this drift was that the bone was greater on the mesial of the osteotomy and when the implant was placed the greater bone density on the mesial forced the implant to drift to the distal. Proper pressure when placing the implant would have prevented this drift.



09/13/2012 Pre op

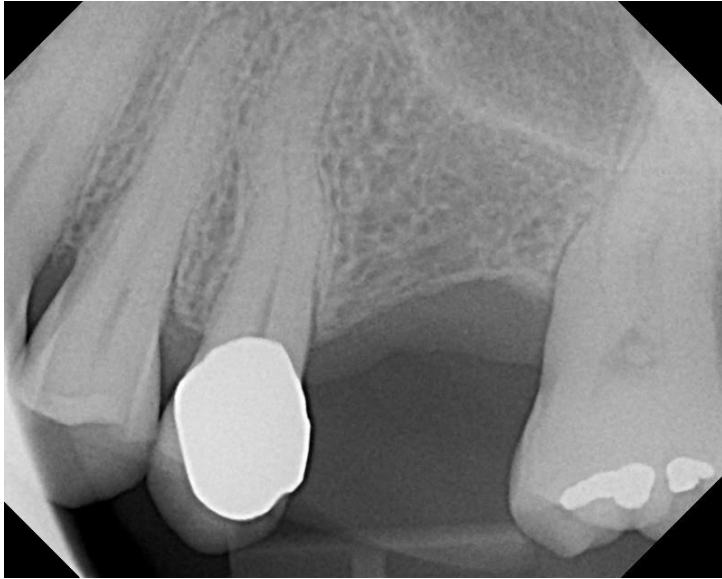


09/13/2012 Steiner Sinus Lift with ridge augmented.

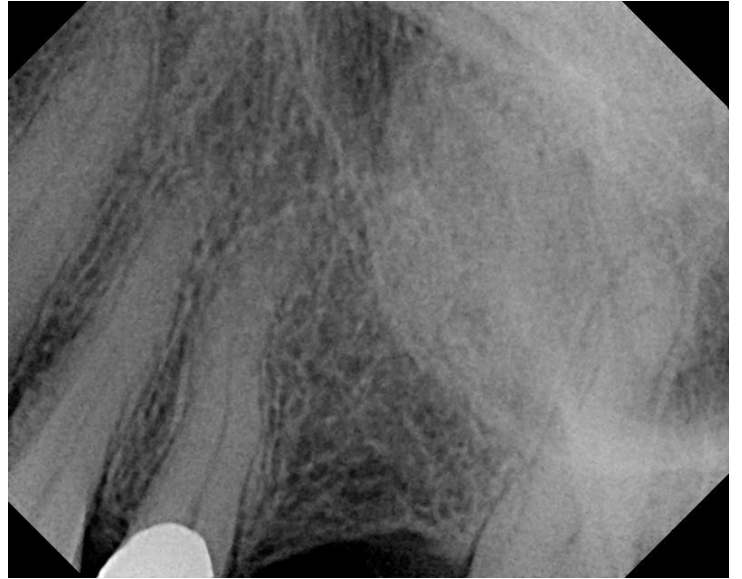

12/11/2012 Healing abutment date.

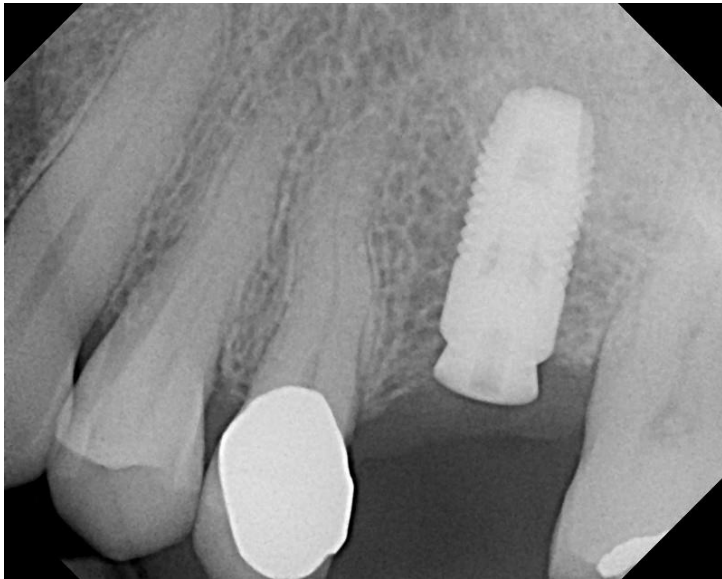
ID: Ros #44



Pre op



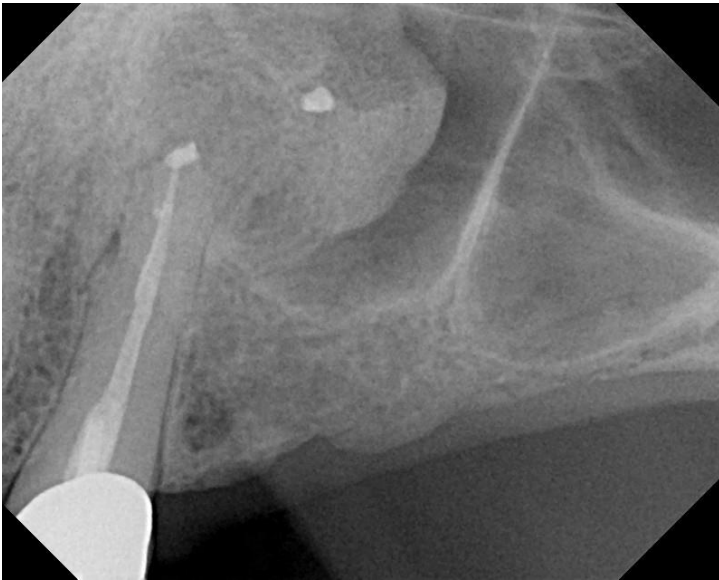10/30/2012 Steiner Sinus Lift complete.



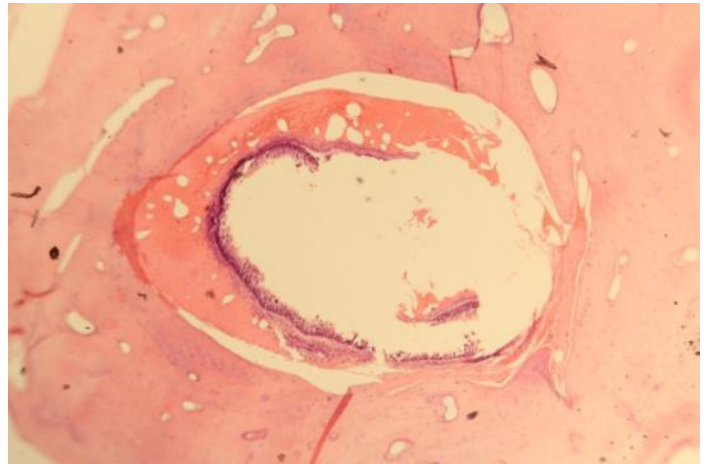
10/30/2012 Steiner Sinus Lift complete with implant.

ID: Cox #45

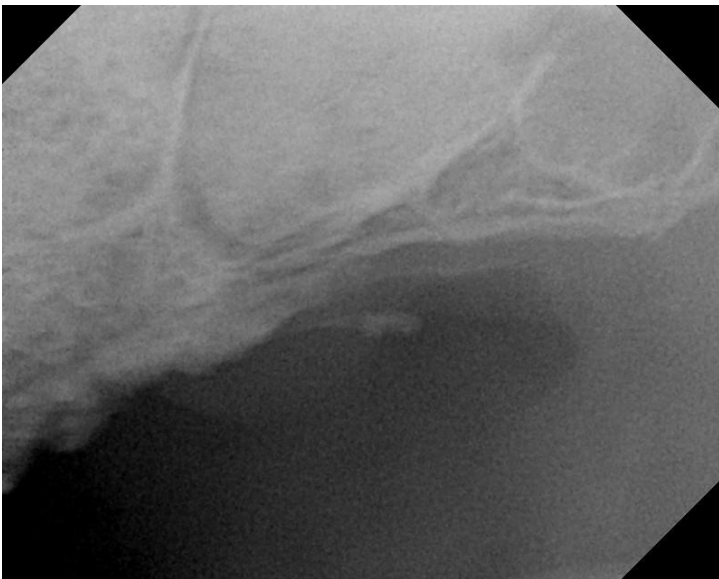
Sinus foreign object



Foreign object noted in left sinus

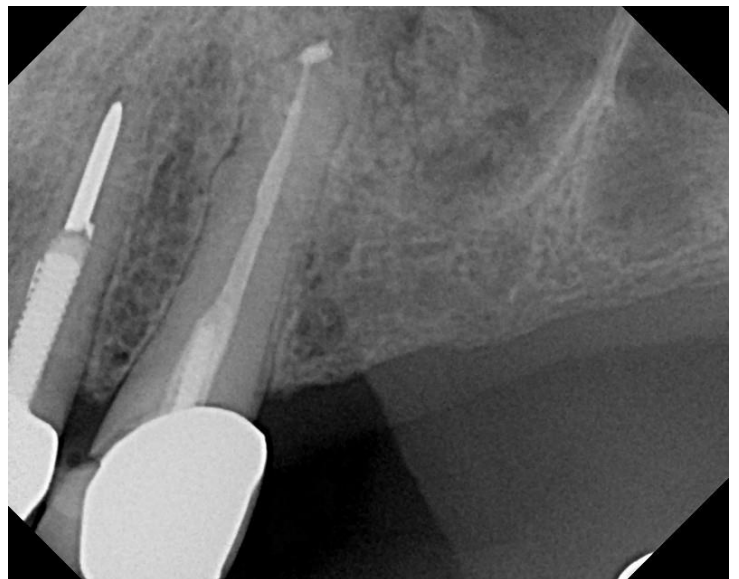

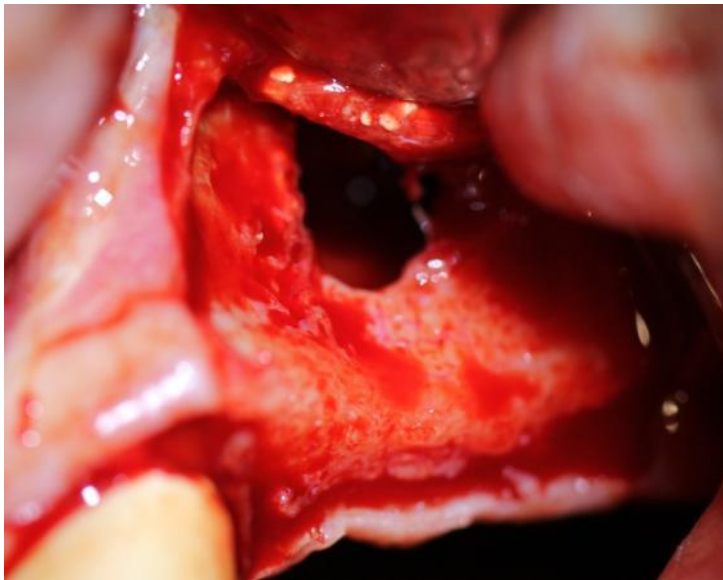
Histology of biopsy shows the foreign object removed but surrounded by monocytes and encased in sclerotic bone.



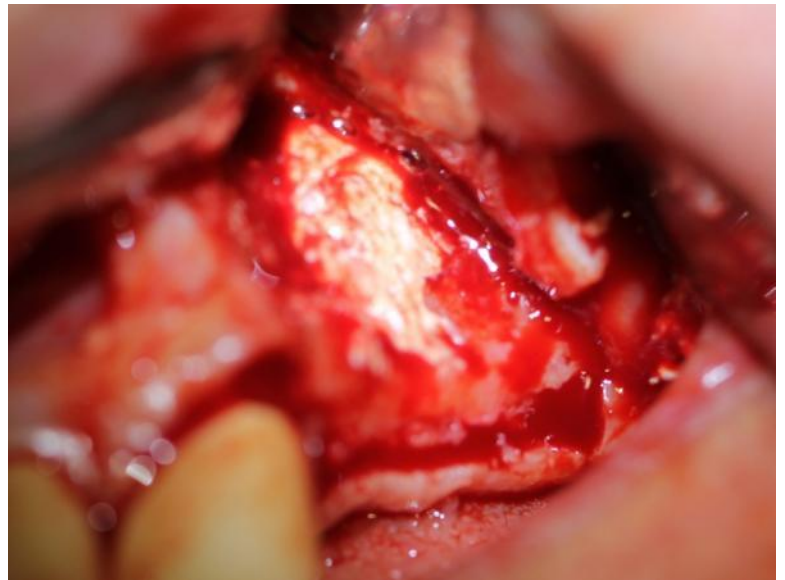
returned for sinus augmentation
regeneration of the sinus membrane.

The site was grafted with Sinus Graft and
Approximately 8 months later, the patient
OsseoConduct BTCP granules to allow for

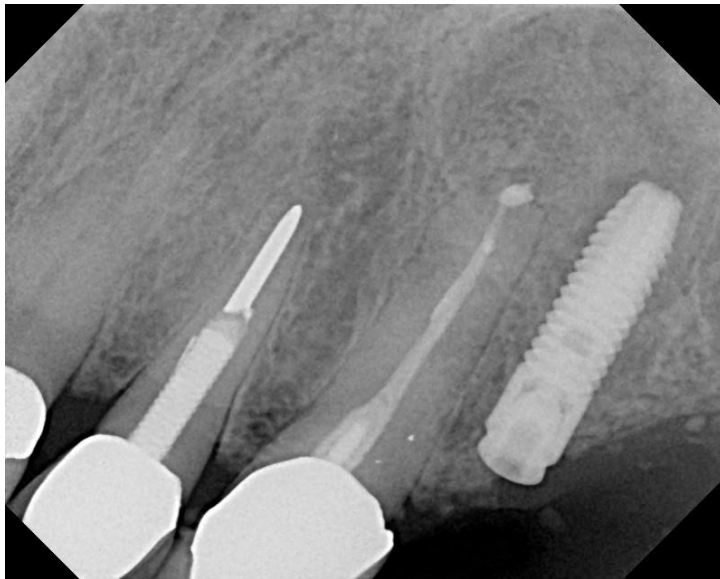



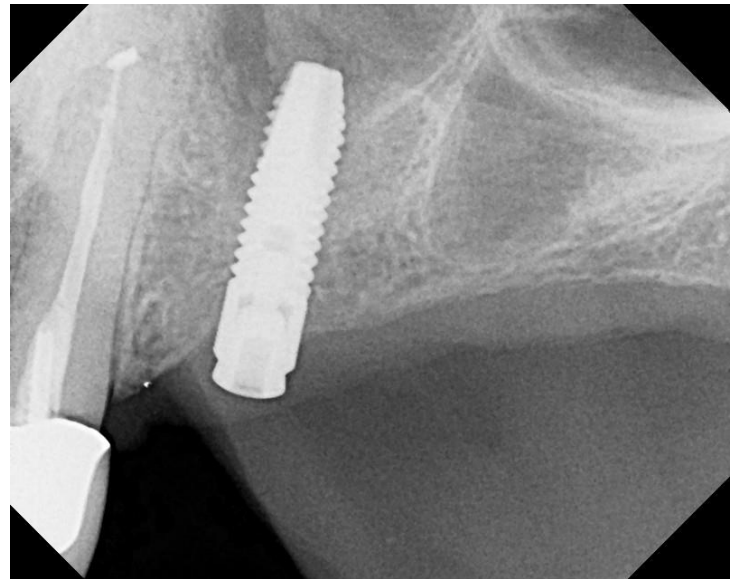
Re-entry



Grafted with Ridge Graft™ and OsseoConduct BTC granules

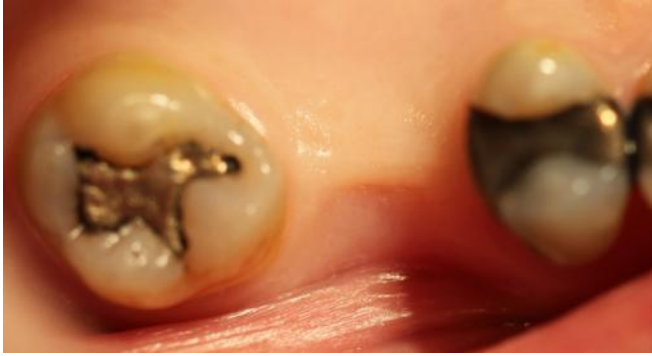

Day of implant placement

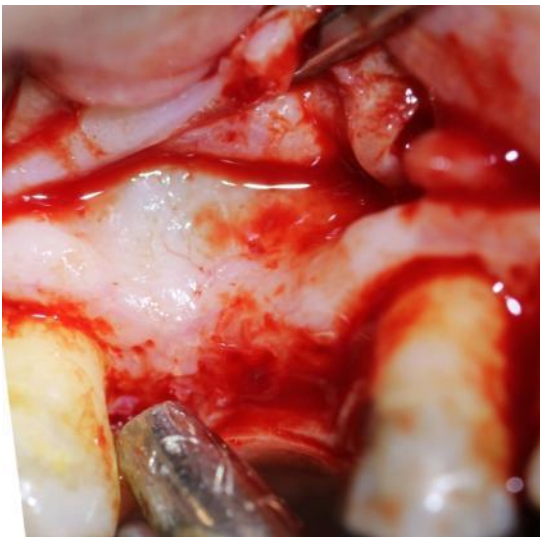
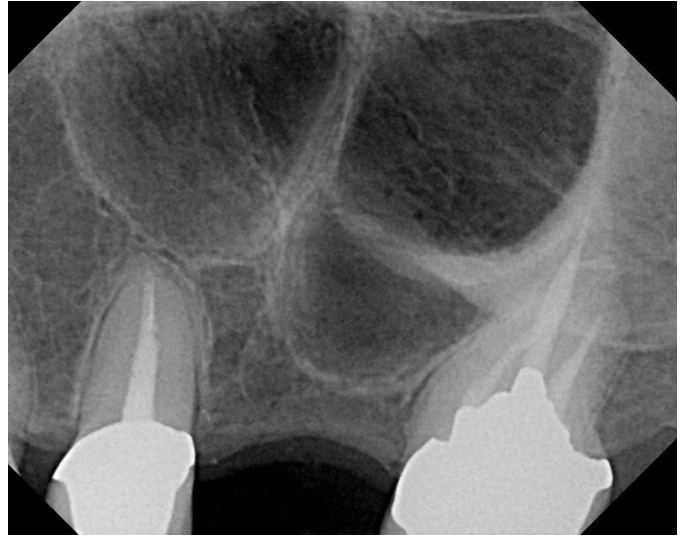


Day of healing abutment placement

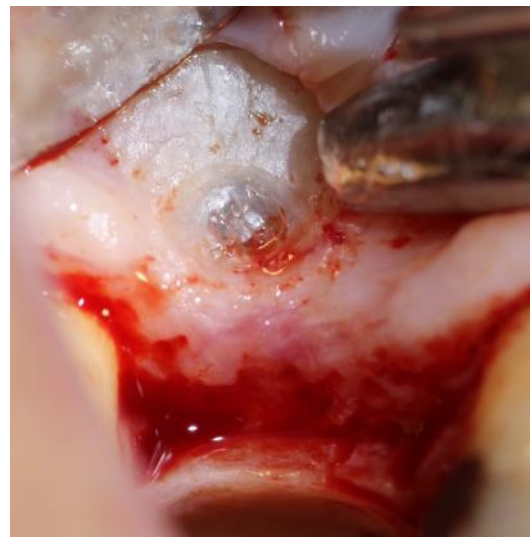The foreign object was determined to be apicoectomy amalgam. The process was believed to be pneumatization of the sinus leaving the sclerotic bone in place around the foreign object as the sinus enlarged. The sclerotic bone was pedunculated off the lateral wall of the sinus and was in the form of a ball only connected to the lateral wall with a pedunculated arm.



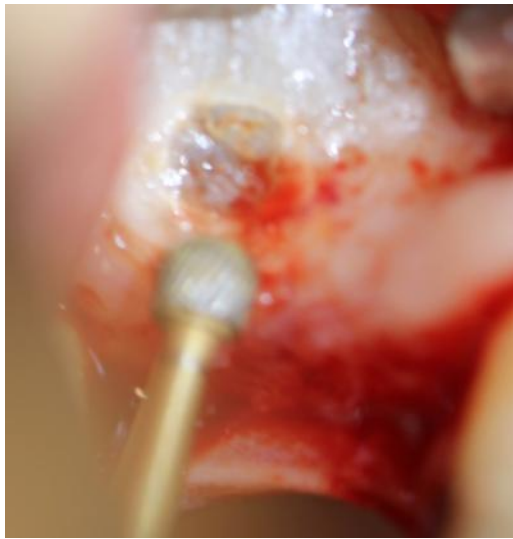This patient presented with a pneumatized sinus and a narrow ridge. The treatment plan was to do a Steiner Sinus Lift and ridge augmentation and then place the implant in 4 months after sinus and ridge augmentation.



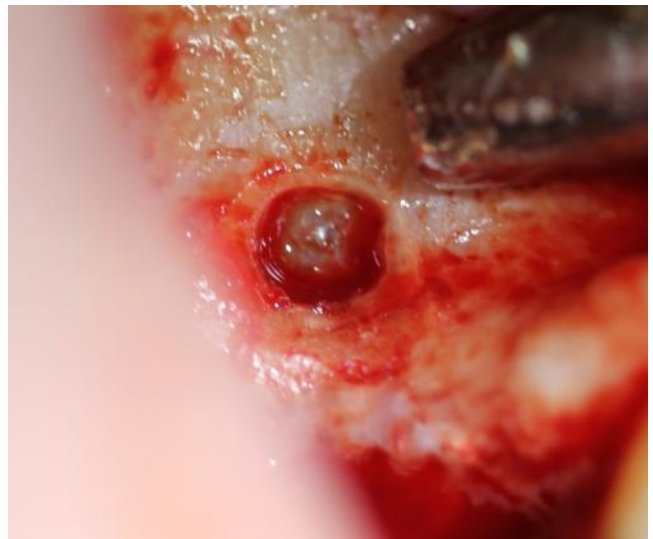
Buccal flap for Steiner Sinus Lift.



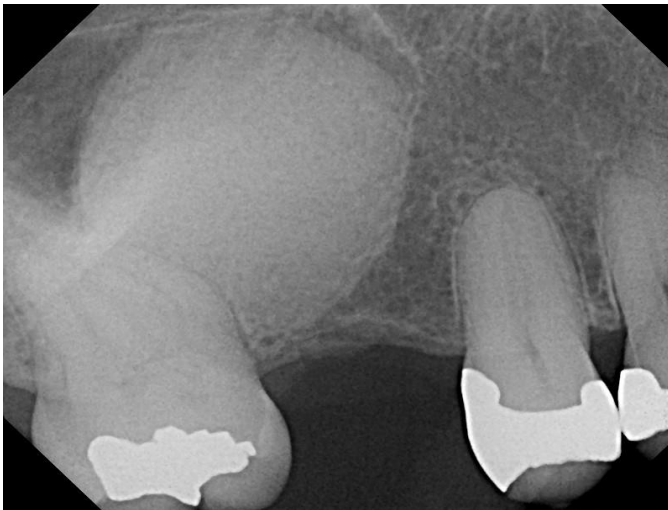The high speed headpiece using a #8 round bur is used to prepare the osteotomy coronal to the floor of the sinus approximately 3 mm in diameter.



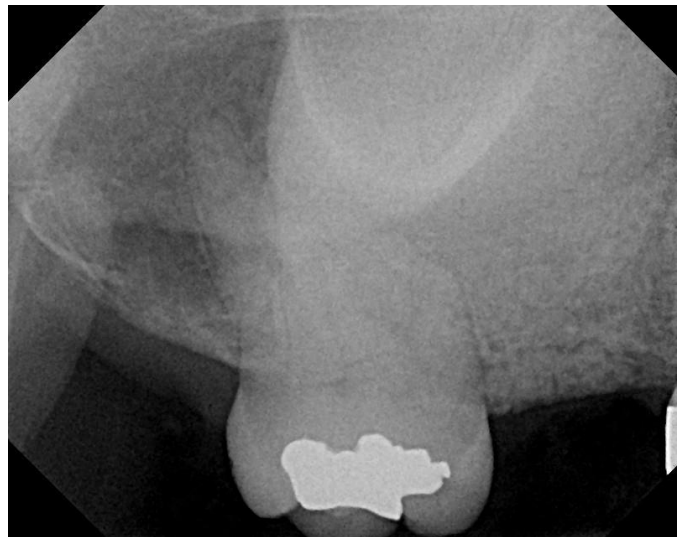After initial prep and the sinus membrane is within one mm, the bur is changed to a #8 multifluted round bur



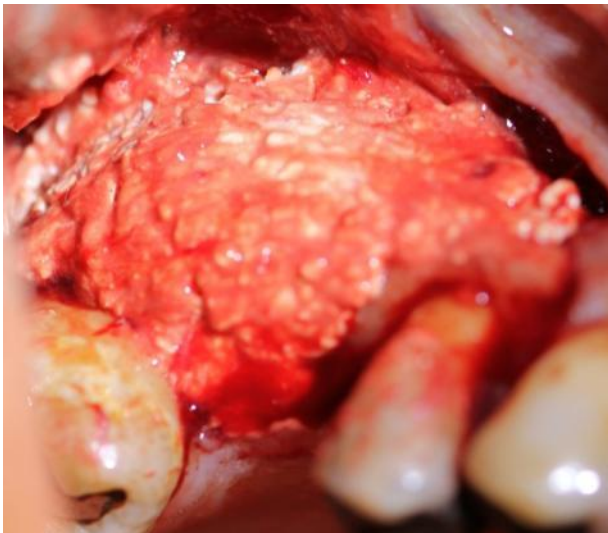
After the multifluted round bur removes the last mm of bone, microsurgical instruments are used to dissect the membrane off of the floor of the sinus to the medial wall.



After the dissection is complete, Sinus Graft™ is injected into the sinus and the sinus membrane is raised



Additional Sinus Graft is injected to complete the sinus augmentation.



The buccal surface of the ridge is grafted with Ridge Graft™ mixed with OsseoConduct Standard BTCP granules. Because Ridge Graft™ is self membranizing, no membrane was used however the use of a synthetic membrane is advised.

ID: Severe #47

This patient presented with chronic severe untreatable sinusitis. During the surgery the bone bleed profusely and the sinus was filled with inflamed tissue. After grafting and implant placement on the UR the patient experienced significant improvement in his sinusitis and choose to proceed with surgery on the UL with similar improvement in his symptoms.

